



Surgery provides viable option for cancer pain relief

by John J. Moossy, M.D.

Pain is a common symptom in patients with cancer. Most patients with cancer have pain which can be controlled by oral medications.

One author who has frequently written about this subject has estimated 90% of patients with cancer related pain can get adequate relief by appropriate use of oral analgesics and adjuvant oral medications such as anticonvulsants, anti-emetics, and other medications to augment the effects of oral analgesics. However, if 70% of all patients with cancer suffer pain moderate to severe at some stage of their illness which requires treatment, then 7% will not get satisfactory relief with oral medication alone.

With 1,268,000 new cancer cases and an estimated 55,000 cancer deaths this year, there may be as many as 40,000 patients who could get improved pain relief through surgical intervention. A substantial number of patients in the early or middle phases of their illness could benefit from a surgical procedure for pain control.

Cancer pain can occur from visceral, bony, or nervous system involvement by the malignancy itself or by agents used to treat the illness, either chemotherapy or radiation treatments. Since the most frequent sight of bony metastatic disease is the spine, there is a subset of patients with spinal metastasis whose bony lesion can

cause neuropathic pain by neural compression or by destabilization of the spine rather than direct nervous system invasion by the malignancy.

Surgical management of cancer pain therefore can be divided into the following three categories:

1) direct surgical approach to resect the malignant lesion causing the pain. This can be part of the treatment of the illness or for pain control alone when spinal instability or direct nervous system invasion has

occurred such as an intramedullary spinal or cranial metastasis.

2) neuro-augmentative surgery which involves the use of either neuro stimulation or intrathecal opioid administration via a surgically inserted pump.

3) neuro-ablative procedures in which a section of the nervous system is deliberately destroyed, usually the neurons or neural pathways responsible for pain registration, to provide pain relief.

The surgical management of direct malignant involvement of either the spine or nervous system is part of the armamentarium of most neurosurgeons. Patients with these types of problems will manifest not only

pain but neurological dysfunction which should lead to an evaluation and an appropriate treatment plan which includes surgical stabilization, resection of the tumor if at all accessible, in conjunction with medical treatment of the illness. With resection of the lesion or stabilization of the spine, most pain problems can be treated using oral narcotics and adjuvant medication.

In the subset of patients who cannot receive satisfactory relief from oral opioid medication and in whom a prolonged survival is expected, consideration of other surgical treatments for pain is appropriate. The neuro-augmentative surgical approaches including electrical stimulation and intrathecal opioid therapy are the most commonly used. Most patients, even with poor response to oral opioid, can get a significant

(see **Surgery...** on page 6)



Dr. Moossy
Associate Professor
of Neurosurgery



▲
“I was walking along the road with two friends. The sun was setting. I felt a breath of melancholy – Suddenly the sky turned blood-red. I stopped, and leaned against the railing, deathly tired – looking out across the flaming clouds that hung like blood and a sword over the blue-black fjord and town. My friends walked on – I stood there, trembling with fear. And I sensed a great, infinite scream pass through nature.”

— Norwegian artist Edvard Munch

Relief
Pain
Cancer

Major clinical trial tests molecularly engineered vaccine for patients with recurrent malignant astrocytomas

by Frank Lieberman, M.D.



▲ **Dr. Lieberman**
Associate Professor
of Neurology and
Medical Oncology

The 21st century begins an exciting time of opportunity for neuro-oncologists, as a variety of treatment strategies based on new understanding of the molecular biology of malignant astrocytomas are entering translational clinical trials. For researchers at the University of Pittsburgh, a major lab effort to develop an effective immunotherapeutic approach has reached the clinic. This trial is assessing a molecularly engineered vaccine for patients with recurrent malignant astrocytomas.

This study is based on the application of rapidly accelerating understanding of the regulatory mechanisms limiting an effective immunologic response to tumors. Cancer immunologists have been attempting to develop effective immunotherapeutic approaches for malignant gliomas for approximately a quarter century. Recent discoveries regarding the molecular signals that regulate the cellular immune response now allow the generation of specific cell-mediated immunity to human astrocytomas. Immunoregulatory molecules, called cytokines, produced by subpopulations of lymphocytes or antigen presenting cells, naturally modulate the response of the immune system to a variety of antigens. If specifically stimulatory cytokines are produced in the microenvironment of human astrocytoma cells, these tumor cells can become targets for cellular immunity. Once a cellular immune response against a patient's autologous tumor is established, cytotoxic lymphocytes can penetrate the infiltrating margin of the tumor and specifically kill residual viable tumor cells. Since the

failing of current treatments for malignant gliomas is the inability to prevent relapse at the margin of the originally treated tumor volume, an effective vaccine approach will represent a major advance.

The gene transfer approach used in this trial, developed by Dr. Hideho Okada (research assistant professor of neurological surgery and co-director of the University of Pittsburgh's Gene Vector Laboratory) uses molecular engineering to introduce the gene for human IL-4 into the patients, autologous tumor cells, which have been expanded in cell culture after surgical removal. Studies in animal models of primary malignant astrocytomas demonstrated that IL-4 was the most effective immunostimulating cytokine when used with a live tumor cell vaccine. In rat models, vaccination with IL-4 transduced tumor cells prolonged survival in animals bearing established tumors, the most rigorous animal model experimental design.

Study participants are evaluated and then followed for the duration of the study by UPMC Brain Tumor Center neuro-oncologists, headed by Dr. Frank Lieberman (associate professor of neurology and medical oncology) and Dr. Ian Pollack (professor of neurosurgery and co-director of the Brain Tumor Center). Dr. Pollack performs the cytoreductive surgery, which is the necessary first component of the protocol. Patients with recurrent malignant astrocytomas or glioblastomas that can be surgically resected are eligible for this trial. Patients must have undergone radiation therapy and may have also been treated with one or more chemotherapy regimens and/or radiosurgery. As long as the tumor is amenable to extensive resection, patients are eligible for study regardless of number of relapses or prior therapies. However, in order to be eligible for the vaccine trial, the patient's tumor-related mass effect must be sufficiently relieved by the resection that the patient can be weaned off of corticosteroids and maintained steroid-free for a period of at least two weeks after surgery.

While the patient is recovering from surgery and being weaned off corticosteroids, Dr. Okada's team expands the tumor cells in cell culture and transects the tumor cells with a retrovirus containing the message for human interleukin-4 (IL-4) and for herpes simplex thymidine kinase (HSV-TK). Then the transfected tumor cells are injected as a live cell vaccine into the patient's thigh. The local immune response at the vaccine site is manifested by induration and inflammation at the site. Patients are followed clinically and by interval MRI scans to assess treatment response and to

▶ **Researchers**
Drs. Hideho Okada,
Frank Lieberman
(seated) and
Ian Pollack



monitor for toxicity of the treatment. Immunologic studies to assess the cellular immune response to the autologous tumor cells are performed at intervals, using peripheral blood. When vaccination is complete, patients are treated with systemic ganciclovir. This treatment employs the HSV-TK gene inserted as part of the retroviral vector as a “suicide gene” for the tumor cells which express it.

Although this is a phase I trial, assessing the safety of the gene transfer vaccine approach, the patients are followed and time to progression assessed. Median time to progression for the study patients will be compared to recent historical controls to give a preliminary estimate of relative efficacy of this approach in comparison with other strategies for treating recurrent malignant gliomas. One patient has already been treated on this protocol, with a prolonged survival after vaccine treatment relative to that expected in a patient with recurrent glioblastoma.

This trial is currently open for patient entry. Patients must have pathologically documented glioblastoma or malignant astrocytoma that is recurring after radiation therapy. Referring physicians may contact Dr. Lieberman (412) 692-2600 or the study nurse coordinator Mark Wargo at (412) 647-5369. ■

BTC targeting malignant gliomas with innovative drug treatments

The University of Pittsburgh Brain Tumor Center is conducting clinical trials of a number of innovative drug treatments for patients with malignant gliomas. Laboratory discoveries in the past 10 years have dramatically refined the understanding of the molecular mechanisms driving astrocytoma cell proliferation, migration, and angiogenesis. These discoveries have led to the development of novel classes of antineoplastic drugs with mechanisms of action very different from classical chemotherapy agents.

Malignant gliomas are among the first tumor types to test these new agents and a number of molecularly targeted drugs are now entering translational clinical trials. The Brain Tumor Center is one of a handful of centers that is a member of the North American Brain Tumor Consortium, which is supported by the National Cancer Institute in its mission to identify and evaluate novel, translationally oriented treatment strategies for patients with malignant brain tumors. These activities are coordinated by Dr. David Schiff, assistant professor of neurological surgery, neurology, and medicine. Current studies of the consortium include SU-5416, an antiangiogenesis agent; R155777, a ras signal transduction blocker; and STI-571, a tyrosine kinase inhibitor (Gleevec).

Patients need not have resectable tumors to be eligible for NABTC protocols. Adult patients with malignant astrocytomas or glioblastomas that have recurred after radiation are eligible. Patients may have received radiosurgery, and depending on the study may have recurred up to two or three times at study entry. Referring physicians may contact Drs. Schiff or Frank Lieberman at (412) 692-2600 or study nurse coordinator Mark Wargo at (412) 647-5369. ■

Spotlight

Todd P. Thompson, M.D.

While at the University of North Carolina Medical School, Todd L. Thompson, was looking for a field that would challenge him throughout his career. Fascinated with the nervous system and the mind, he chose neurosurgery over other surgical subspecialties. Now, after seven “arduous years” of specialty training at the University of Pittsburgh Department of Neurosurgery, Dr. Thompson has completed his residency and is ready to move on to meet the challenges that first piqued his interests.

During training, Dr. Thompson assisted with more than 1500 operations, authored 20 neurosurgical publications, and completed an intradepartmental fellowship in image-guided and gamma knife radiosurgery under the direction of Drs. L. Dade Lunsford and Douglas Kondziolka. Dr. Thompson also studied neurosurgery for three months at the University of Nagoya, Japan sponsored by the Sugita Scholars program.

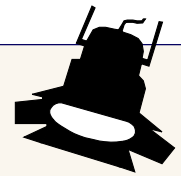
Soon after graduation this past June, Dr. Thompson left his childhood home of Pittsburgh to begin his career as the Chief of Neurosurgery at the Straub Hospital and Clinic in Honolulu, Hawaii. “I am extremely excited about the opportunity to build a neurosurgical center of excellence using the knowledge and skills that I acquired at the University of Pittsburgh.” Dr. Thompson says that he plans to use a variety of special procedures that he learned in Pittsburgh including gamma knife radiosurgery, endoscopic pituitary surgery, microvascular decompression, minimally invasive spine surgery, and instrumented spine fusions.

His future looks exceedingly bright. “Todd is a man with tremendous intellectual abilities meshed with a natural surgical skill that is unsurpassed,” comments Dr. Lunsford, chairman of neurological surgery. “This is blended with a personality blessed with humor and equanimity. We should all be so lucky.”

Dr. Kondziolka adds, “Todd exemplifies so many of the characteristics of residents in our training program. He is knowledgeable, motivated, good with patients and their families, and a skilled surgeon. His wide-ranging surgical skills together with a special interest in gamma knife radiosurgery and functional neurosurgery will be of great value to the people of Hawaii.”

Neurosurgery training is not all work however. “One of the wonderful surprises of my residency was meeting my wife, Diane, during the first year of training.” Dr. Diane Thompson is a psychiatrist at Magee Womens Hospital specializing in the care of women with cancer. In Honolulu, she will continue her work as an associate professor of psychiatry at the University of Hawaii and the Director of Science for Queen’s Medical Center.

Dr. Thompson is currently a resident member of the American Association of Neurological Surgeons, the Congress of Neurological Surgeons, and the American Society for Neural Transplantation & Repair. In 1999, he was elected to the Young Neurosurgeons Committee of the AANS. ■



CyberKnife® offers frameless stereotactic radiosurgery, marking revolutionary new way to treat spine lesions

by Peter Gerszten, M.D., M.P.H.



Dr. Gerszten
Assistant Professor
of Neurological Surgery

Focused radiation, known as stereotactic radiosurgery, has become a commonly used tool for a wide variety of both benign and malignant lesions within the cranium. Its limitations to lesions within the skull has been due to its reliance upon a rigid external frame attached to the skull for determining spatial coordinates.

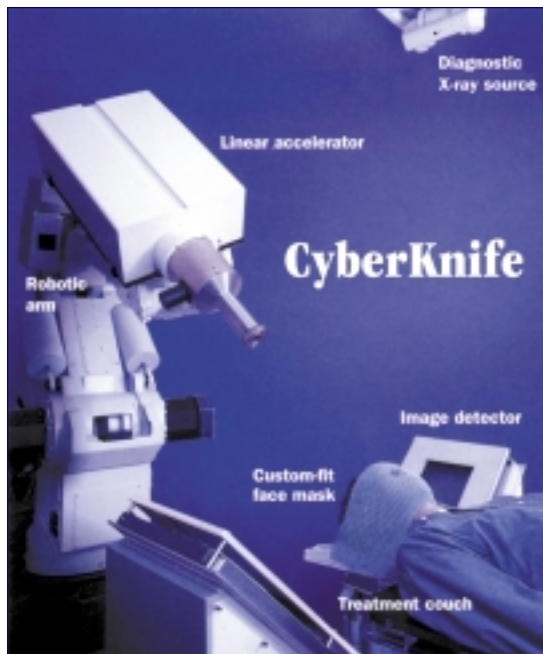
A new device, now available at UPMC Shadyside, allows for frameless radiosurgical procedures of the spine. This concept, based upon guided missile technology, is incorporated in a new form of stereotactic radiosurgery called the CyberKnife®, manufactured by Accuray, Inc. of Sunnyvale, CA.

What is the CyberKnife®?

The CyberKnife® combines two advanced technologies to deliver frameless conformal radiosurgery. The first is a lightweight linear accelerator designed for radiosurgery and mounted to a highly maneuverable robotic system. The second innovation is near real-time image guidance that eliminates the need for skeletal fixation to rigidly immobilize the target.

This system requires radiographs of the treatment site's skeletal features, uses image registration techniques to determine the treatment site's coordinates with respect to the linear accelerator, and transmits the target coordinates to the robot which then directs the beam to the treatment site. When the target moves, the process detects the change and corrects the beam pointing in near real-time.

▶ *The CyberKnife®, based upon guided missile technology, is incorporated in a new form of stereotactic radiosurgery. (Courtesy Accuray)*



The imaging hardware is comprised of two fixed diagnostic fluoroscopes. They provide a stationary frame of reference for locating the patient's anatomy which, in turn, has a known relationship to the reference frame of the robot and linear accelerator. The CyberKnife® determines the location of the skull or spine in the frame of the radiation delivery system by comparing digitally reconstructed radiographs derived from the treatment planning images with radiographs required by the real-time imaging system.

Once skeletal position is determined, the coordinates are related to the robot, which adjusts the pointing of the linear accelerator, and radiation is delivered. The speed of the imaging process allows the system to detect and adjust to changes in target position in less than one second. The linear accelerator is then moved to a new position and the process is repeated.

The CyberKnife® is currently available for treatment of lesions throughout the cervical spine. These lesions may be benign or malignant such as metastases, meningiomas, and arteriovenous malformations. The CyberKnife® has been used to successfully treat metastatic lesions in patients who are otherwise not candidates for surgery or for lesions that are not amenable to open surgical techniques.

How does the treatment process work?

Treatment with the CyberKnife® begins as the patient undergoes a CT or MRI as an outpatient. The imaging is transferred to a workstation where a treatment plan is prescribed. The patient then returns several days later for the actual treatment. The actual treatment time takes approximately one hour. No sedation is necessary as the patient is able to comfortably lie on the table throughout the procedure.

The CyberKnife® is a revolutionary new way of treating lesions of the spine. Just like the Gamma Knife allowed for the successful treatment of a variety of benign and malignant brain lesions that would otherwise involve open surgical techniques, the CyberKnife® allows for a highly precise and large amount of radiation to be focused on a lesion, allowing for minimal exposures of normal tissues to radiation.

Research is currently in progress at our institution in developing the CyberKnife® for use in the thoracic and lumbar region as well. Preliminary experience using this more complicated technology is promising. Patients who might be candidates for CyberKnife® radiosurgery should be referred to Dr. Peter Gerszten at (412) 647-0958. ■

Lingual artery embolization provides useful intervention in cases of uncontrollable post-tonsillectomy bleeding

by Michael B. Horowitz, M.D., Elad I. Levy, M.D. and Anne M. Cahill, M.D.

An estimated 4,300 cases of postoperative hemorrhage following tonsillectomy occur in the United States each year. The reported incidence of postadenotonsillectomy hemorrhage that requires surgical control ranges between 5 and 20%. The scope of this notable morbidity has remained largely uninfluenced by and independent of modern surgical techniques and medication. Comparisons of various surgical techniques — including bipolar and monopolar dissection, laser tonsillectomy, and obliteration of the tonsillar fossa by suturing the faucial pillars — have shown that these procedures produce different degrees of intraoperative blood loss and postoperative pain, but they have not demonstrated any significant differences in postoperative hemorrhage rates. Agents such as fibrin glue have also been used to reduce the incidence of postoperative hemorrhage, but results thus far have been inconclusive.

A healthy 10-year-old girl came to our institution with a history of chronic mouth breathing, stridorous snoring, and recurrent sore throat. She had had two previous episodes of tonsillitis, which were treated with appropriate antibiotics, and she had recently developed intermittent obstructive sleep apnea. The physical examination was significant only for a deviated septum seen on anterior rhinoscopy and large tonsils (4+) bilaterally. We performed a routine adenotonsillectomy for adenotonsillar hyperplasia, which resulted in an estimated blood loss of 50 ml. The patient was discharged home the same day.

Three days later, the patient returned to the emergency room following two episodes of bright red bleeding from her mouth; each episode had resolved spontaneously. She was observed overnight and explored in the operating room the following morning. A large clot was removed from the left resection bed, and hemostasis was achieved. However, in the recovery room, the girl spontaneously hemorrhaged approximately 1,500 ml from her oropharynx. An emergent tracheotomy was performed. Once the patient was stabilized, she was taken immediately to the angiography suite. Angiography with oropharyngeal contrast extravasation revealed that the left lingual artery was disrupted (figure 1, left).

To control the bleeding via an endovascular route, we placed a 6F sheath in the right femoral artery. A 6F Envoy guiding catheter was advanced into the left internal carotid artery. A 0.018-inch RapidTransit microcatheter was then advanced over a 0.016-inch

microwire, and the left lingual artery was selectively catheterized. The vessel was then embolized and sacrificed with the aid of Guglielmi detachable coils until the anterograde flow was arrested. We used these coils because they allow for complete control of the coils until they are detached. This reduces the risk of an inadvertent coil migration into the internal carotid artery. Migration occurs when a catheter becomes dislodged from its tenuous position in the lingual artery and recoils into the internal carotid artery.

Once the vessel was occluded (figure 2, below), we removed the packing from the oropharynx and inspected the left tonsillar bed. A coil could be seen protruding out of the mucosa, and it was removed. Hemostasis was confirmed. Repeat imaging demonstrated a gap in the coil mass that was left by the missing coil (figure 3). This observation confirmed the fact that the patient had a side-wall type vascular injury.

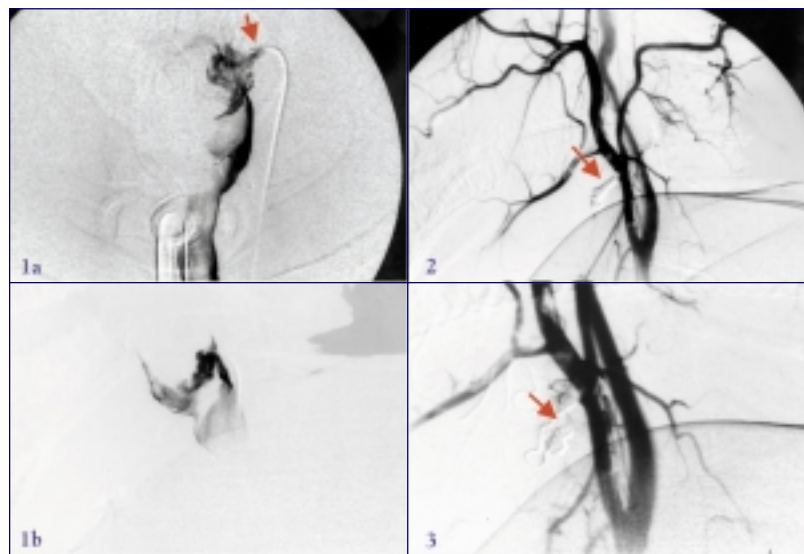
The patient was observed in the intensive care unit and discharged from the hospital 12 days later in excellent condition (figure 4 on page 6).

Postsurgical hemorrhage is responsible for the majority of post-tonsillectomy fatalities. Significant risk factors include older age, chronic tonsillitis, excessive

(see *Coil Embolization...* on page 6)

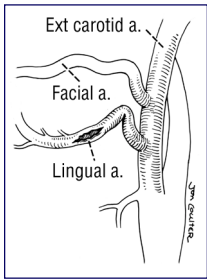


▲
Dr. Horowitz
Co-Director,
Center for
Neurointerventional/
Neuroendovascular
Therapy (CNNET)



▲
Pre-embolization AP (figure 1a) and lateral (1b) left lingual artery selective arteriograms demonstrate contrast extravasation into the oropharynx (arrowhead). Lateral-view arteriogram (2) of the left common carotid artery shows the coil occlusion of the left lingual artery (arrowhead). Left common arteriogram (3) shows the gap in the coil mass where a coil was removed after it had protruded through the lingual artery side hole into the oral mucosa (arrow). The arrow points to the residual packing, not a coil.

Coil embolization effective in persistent post-tonsillectomy bleeding



▲
(Figure 4)
Drawing depicting the disruption of the lingual artery side wall.

(from page 5)

intraoperative bleeding, and an elevated postoperative mean arterial pressure. Szeremeta et al found that postoperative bleeding occurred in 2.8% of patients who underwent electrocautery tonsillectomy and 7.6% of patients who underwent mechanical tonsillectomies. Others have not found that postoperative hemorrhage rates correlate with operative technique.

There is a general consensus regarding the management of postsurgical tonsillar bleeding. In 1995, Cressman and Myer surveyed 17 pediatric otolaryngology fellowship programs (100% response) and found that (1) most favor admission for observation; (2) there is little difference in the method of managing immediate and delayed hemorrhage; (3) removal and inspection of clots is recommended when they occur in the tonsillar fossa; (4) approximately two-thirds of respondents attempt to control active bleeding in the emergency room, whereas the rest proceed directly to the operating room; (5) after multiple episodes, a full hematologic evaluation is warranted; and (6) the age and the cooperativeness of a child is an important determinant in the decision-making process.

The importance of the case described here is the finding that surgical control of delayed postoperative tonsillar bleeding was not successful because of the etiology of the hemorrhage—a side-wall tear in the lingual artery. Four other reports in the literature—two in the English language—have described the use of coil embolization for uncontrollable tonsillar bleeding. Two of these reports described the treatment of iatrogenic pseudoaneurysms—one in the internal carotid artery,

and one in the lingual artery. These reports, in addition to ours, suggest endovascular therapy as a useful intervention when post-tonsillectomy bleeding persists despite routine interventions. Coil embolization of bleeding vessels can also minimize morbidity following this common, well-described operative complication. ■

Surgery an option for cancer pain

(from page 1)

therapeutic response from intrathecal opioid which is the mainstay of neuro-augmentative surgery in cancer patients. This involves a trial period of intrathecal administration of selected opioids available for intrathecal use. These include Morphine, Dilaudid, and Fentanyl. Other agents that can be used in the intrathecal compartment include Bupivacaine—a long acting local anesthetic—and Clonidine—an alpha adrenergic blocking agent). Other medications are currently under investigation but are not available for general usage.

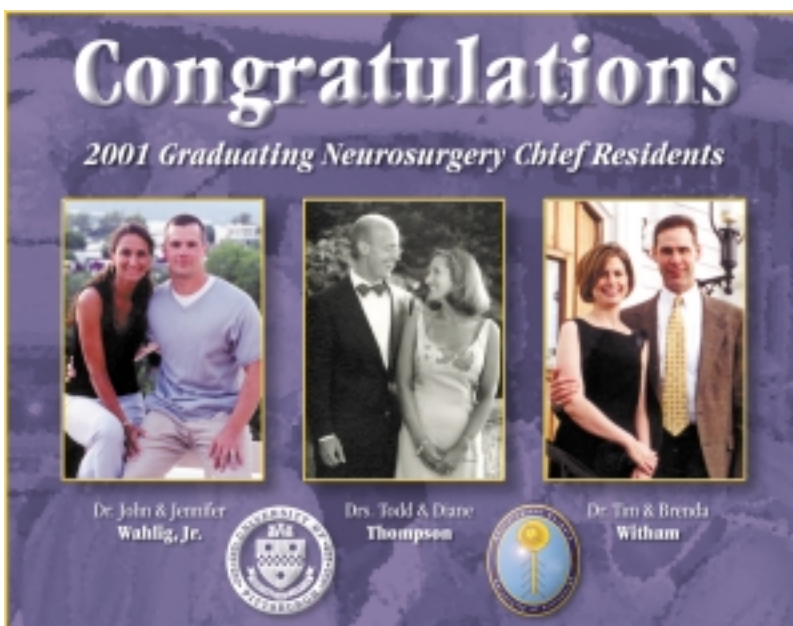
The combination of a surgically implanted catheter and pump system with or without oral therapy can provide pain relief to the majority of patients with diffuse pain syndromes that are not responsive to oral medications. For those patients near the end of their lives a spinal catheter attached to an external pump is another option for pain control.

A smaller subset of patients who do not respond to neuro-augmentative surgical procedures or direct surgical attack can be considered for neuro ablative procedures.

The cranial procedures include sensory corticectomy, cingulumotomy, thalamotomy, hypothalamotomy, and hypophysectomy. The spinal procedures include cordotomy, myelotomy, dorsal root entry zone lesioning, and peripheral procedures include rhizotomy and neurectomy.

Cordotomy is designed for hemibody pain below the level of the clavicles. This can be done as a percutaneous procedure at C1-2 or as an open procedure in the cervical or thoracic regions if indicated. A commissural myelotomy disrupts the pain conducting fibers as they traverse the spinal cord and can be useful for bilateral lower extremity or pelvic pain. Hypophysectomy, either surgical or chemical, can be useful in hormonally mediated pain problems associated particularly with breast and prostate cancer.

The mainstay of the surgical treatment of cancer induced pain remains the administration of intrathecal opioids and can be a useful adjunct in the palliative care of the patient. ■



Awards and Recognition:

Dr. Hideho Okada, research assistant professor, has been announced as one of this year's fifteen recipients of the Clinical Scientist Development Award presented by the Doris Duke Charitable Foundation. The award is presented by the foundation to help prepare and support new investigators as they begin their careers as independent clinical researchers. The program, inaugurated in 1998, is limited to the development of clinical researchers in cardiovascular diseases, cancer, AIDS, and sickle cell anemia and other blood disorders.

Dr. Elizabeth Tyler-Kabara, fourth-year resident, has been selected as the Neuro ICU Resident of the Year at UPMC Presbyterian. Dr. Tyler-Kabara was cited for her "outstanding contribution" to patients and families and for demonstrating "unfailing commitment to quality in the care that she provides."

Cairn Marsh, 5G neurosurgery unit nurse, was selected as this year's UPMC Presbyterian representative to the Cameos of Caring Awards Gala presented by the University of Pittsburgh School of Nursing. The gala recognizes outstanding bedside nurses for their commitment to quality patient care, role model stature and patient advocacy. Nurses from 29 western Pennsylvania hospitals are selected for the gala scheduled for October 6 at the Hilton Hotel in downtown Pittsburgh.

Dr. P. David Adelson was recognized by the Critical Care Staff at Children's Hospital of Pittsburgh as an "Outstanding Surgeon." This recognition is based on leadership, teamwork, communication skills and the ability to educate staff and families.

Recent Grant Awards:

- "Efficacy of Ventricular Catheters Impregnated with Minocycline and Rifampin versus Standard Ventricular Catheters in the Reduction of Catheter Infection," **Dr. Donald Marion** from Cook, Inc. (\$120,000). Study intended to show that minocycline and rifampin coated ventricular catheters are safe and superior to untreated standard ventricular catheters in reducing the rate of ventriculitis in humans.

Media:

- **Dr. William Welch** was interviewed by Marilyn Brooks of WTAE-TV (Pittsburgh) on May 2 regarding his work with MacroPore implants, a flexible material designed to help facilitate better and faster bonding of bone material.

- **Dr. Michael Horowitz** was also interviewed by Brooks on May 15 concerning his and **Dr. Amin Kassam's** work with microvascular decompression in hemifacial spasm cases.

- On May 24, Reuters Health News Service reported on a University of Pittsburgh trial studying the use of stents to prop open diseased arteries of seriously ill stroke patients.

Drs. Horowitz, Elad Levy, Christopher Koebbe and Charles Jungreis are involved in the study.

New Employees:

Sheri Willis, health professional for Dr. Welch; **Louise Foreman**, secretary for Drs. Kassam and Horowitz; **Jerome Lee**, student worker in administration; **Gordon Burk**, student worker in administration; **Annette Norbut**, secretary to Dr. Matt El-Kadi. Welcome back to **Art Nestler**, outpatient nurse coordinator for Drs. Welch and Peter Gerszten.

Announcements:

- **Dr. Adelson** was recently accepted into the American Academy of Pediatrics.

- **Dr. Welch** was inducted into the Neurosurgical Society of America June 7 in Amelia Island, Florida.

- **Drs. Douglas Kondziolka and Howard Yonas** were made members of the Society of Neurological Surgeons.

Congratulations:

New baby girl (Rachel, February 16) to **Dr. Welch** and wife Bonnie; marriage for **Darla Kaczmarek**, administrative assistant to Dr. Marion, to Michael McGivern (May 5); marriage for **Dr. John B. Wahlig, Jr.**, chief resident, to Jennifer Poland (May 12); marriage for **Melissa Kachmar**, resident coordinator, to Scott Lukehart (June 16); MBA degree (University of Pittsburgh) to **Maureen Hatch**, grants manager; new baby girl (Evelyn, June 14) to **Drs. Alan and Meera Scarrow**.

Traffic Alert:

Boulevard of the Allies, a major artery for commuters traveling from the north to UPMC Presbyterian in Pittsburgh, is closed eastbound for construction from the Liberty Bridge to Oakland until fall 2001. A suggested detour takes drivers

through the northern end of downtown Pittsburgh. Follow I-279 south to Exit 8A (Veterans Bridge/I-579). Once across the bridge, take the 6th Avenue exit. Turn left onto 6th Avenue. At the fourth traffic light (Forbes Avenue) turn left. Continue on Forbes approximately 2.1 miles then turn left onto Atwood Street. Travel one block and then turn left onto Fifth Avenue. Take the first possible right turn, onto Lothrop Street. Continue to Victoria Street. For valet parking turn right onto Victoria; for self-parking continue on Lothrop to one of the garage entrances.

Please allow an additional 15-30 minutes for your commute dependent on the time of day. For more driving instructions and maps, visit our website at www.neurosurgery.pitt.edu/contact/directions.html.

Upcoming Events:

- July 27-29: "New Developments in Sports-Related Concussion" conference will be held at the Hilton Hotel in downtown Pittsburgh. This conference is designed for physicians, athletic trainers, psychologists, coaches and all others involved in the evaluation and treatment of athletes. Call (412) 647-8220 for more information. ■



Department of Neurological Surgery
University of Pittsburgh
UPMC Presbyterian/Suite B-400
200 Lothrop Street
Pittsburgh, PA 15213
(412) 647-3685

Douglas Kondziolka, M.D., *Editor*
Paul Stanick, *Production Editor*



Patient Referrals
(412) 647-3685



Non-Profit
Organization
U.S. Postage
PAID
Permit #4166
Pittsburgh, PA

The Faculty of the University of Pittsburgh Department of Neurological Surgery:

Professors

L. Dade Lunsford, M.D.
(*Chairman*)
A. Leland Albright, M.D.
Hae-Dong Jho, M.D., Ph.D.
Douglas Kondziolka, M.D., M.Sc.
Donald W. Marion, M.D., M.Sc.
Walter D. Obrist, Ph.D.
(*Emeritus*)
Ian F. Pollack, M.D.
Robert Sclabassi, M.D., Ph.D.
Howard Yonas, M.D.
(*Vice Chairman, Academic Affairs*)

Associate Professors

P. David Adelson, M.D.
C. Edward Dixon, Ph.D.
Michael Horowitz, M.D.
Larry W. Jenkins, Ph.D.
Donald Krieger, Ph.D.
John J. Moosy, M.D.
John K. Vries, M.D.
William C. Welch, M.D.

Assistant Professors

Jeffrey Balzer, Ph.D.
David Bissonette, P.A.-C., M.B.A.
(*Assistant Chairman/Executive Director*)
Donald J. Crammond, Ph.D.
Peter Gerszten, M.D., M.P.H.
Glenn Gobbel, D.V.M., Ph.D.
Amin Kassam, M.D.
Joseph T. King, Jr., M.D., M.S.C.E.
Ann H. Maitz, M.Sc.
Michael J. Rutigliano, M.D., M.B.A.
David Schiff, M.D.
Harold B. Weiss, M.S., M.P.H., Ph.D.

Clinical Professors

Joseph C. Maroon, M.D.
(*Vice Chairman*)
Peter Sheptak, M.D.
(*Vice Chairman, Clinical Affairs*)

Clinical Associate Professor

Adnan A. Abla, M.D.

Clinical Assistant Professors

Ghassan K. Bejjani, M.D.
Matt El-Kadi, M.D., Ph.D.
Daniel A. Wecht, M.D.

Research Professor

Edwin Nemoto, Ph.D.

Research Associate Professors

John Herron, Ph.D.
Mingui Sun, Ph.D.

Research Assistant Professors

Hideho Okada, M.D., Ph.D.
Ronda Pindzola, Ph.D.
Ajay Niranjana, M.Ch.

Visiting Assistant Professor

Anthony Fabio, Ph.D.

Research Instructor

Wendy Fellows-Mayle, M.A.

All *University of Pittsburgh Neurosurgery News* content is copyrighted and is meant solely for the educational purposes of the reader. Please consult your physician before taking any medical actions, or contact the Department of Neurological Surgery at (412) 647-3685. You can also send us e-mail at info@neuronet.pitt.edu.