



## Comprehensive cancer care requires a multi-specialty approach

by Douglas Kondziolka, MD  
Co-director, Center for Image-Guided Neurosurgery

**B**rain metastases are the commonest type of intracranial tumor. Each year, the number of brain tumor metastases diagnosed far outnumbers the total number of other intracranial tumors. Further complicating the clinical picture is the fact that between 21% and 86% of patients with metastases to the brain either have or will develop multiple lesions. In the United States alone, it is estimated that more than 300,000 patients develop brain metastases each year. With the advent of improved cancer treatments for extracranial disease and the proliferation of neuroimaging technology, this overall incidence is likely to rise.

Prior to 1990, traditional treatment options for patients with brain metastases included symptomatic medical management with corticosteroids, surgical resection, and whole brain radiation therapy (WBRT). Unfortunately, when used alone, these treatments were associated with median survivals of three to six months.

Although two randomized trials suggested improved survival and functional status with a combination of surgical resection and WBRT as compared to WBRT alone, a third and larger randomized trial demonstrated no significant survival benefit associated with the addition of surgical resection to WBRT. The development of treatment strategies that exceed historically palliative measures and lengthen patients' survival has been the focus of much investigation.

In most patients with metastatic brain disease, concomitant active systemic disease is common. As such, aggressive intervention

coupled with a low morbidity rate is desirable. Since brain metastases are frequently easily identifiable as well demarcated lesions on either contrast enhanced computerized tomography (CT) or magnetic resonance imaging (MRI), they are commonly amenable to stereotactic radiosurgery.

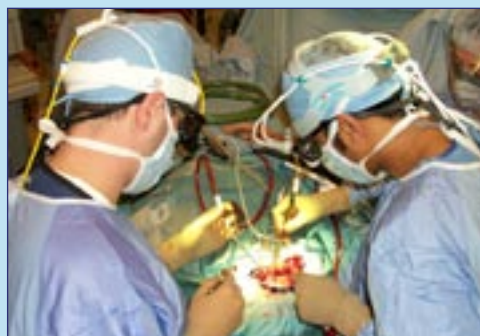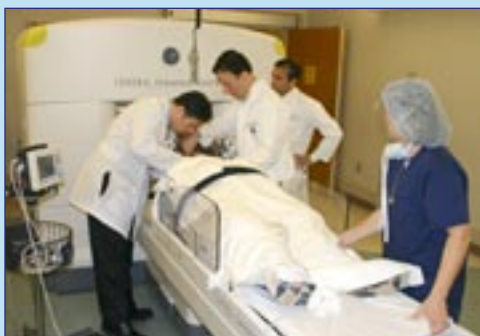Radiosurgery has become a valuable approach for such patients not only because of efficacy in the brain, but because the patient can immediately continue with extracranial cancer care. Success in both the brain and the body are necessary for the best patient outcomes. Although median survivals remain problematic, it is clear that more and more patients are living longer when the brain and body cancer are brought into control. The importance of regular brain imaging (for staging or follow-up), close collaboration with the patients medical oncologist and radiation oncologist, and attention to quality of life issues are crucial.

The development of a brain metastasis is a common complication of active systemic cancer. The most common primary tumors that metastasize to the brain are lung, breast, melanoma, renal, and colon cancer. In a summary of multiple autopsy studies, the mean percentage of patients who develop brain metastasis from the four major primary cancers are as follows: 33% with a lung cancer primary develop a brain metastasis; 21% with breast; 48% with melanoma; and 11% with renal. More rarely, other cancers such as prostate, bladder, ovarian or sarcoma metastasize intracranially. As cancer patients live longer as a result of improved therapy for extracranial disease, the incidence of brain metastasis is likely to increase.

The average age for developing a brain metastasis is approximately 60 years old, although more and more younger patients are being diagnosed, predominantly with melanoma or breast cancer. Lung cancer is the most common source of brain metastasis for men. However, breast cancer is the most common source for women. Most types of cancers appear to metastasize to the same degree in men as women. The distribution of metastasis locations corresponds approximately to the size and blood flow patterns of the brain. This regional tumor distribution is as follows: 80% to 85% in the cerebral hemispheres; 10% to 15% in the cerebellum; 3% to 5% in the brainstem. Autopsy studies show that 60% to 85% of patients who die from cancer have multiple brain metastases.

The time interval between diagnosis of the primary malignancy and a brain metastasis varies substantially, and it appears to be dependent in part upon tumor histology. Patients with lung cancer who go on to develop a brain metastasis tend to do so at a median of six to nine months after diagnosis of the primary. Renal brain metastases are typically diagnosed 12 months from detection of the primary. Colon, breast, and melanoma brain metastases are usually diagnosed two to three years following discovery of the primary malignancy. On the other hand, some patients may present with symptomatic brain metastasis before any primary has been diagnosed. A thorough evaluation of patients with the suggestion of brain metastasis on imaging studies should include a history and physical, chest, abdomen, and pelvic CT, and blood tests

(See *multi-specialty* on page 8)



Gamma Knife radiosurgery (left), resection (middle), and the team approach (right), Drs. Douglas Kondziolka and John Flickinger.

**Professors**

L. Dade Lunsford, MD  
(Chairman)  
P. David Adelson, MD  
(Vice Chairman, Research)  
A. Leland Albright, MD  
C. Edward Dixon, PhD  
Douglas Kondziolka, MD, MSc  
(Vice Chairman, Education)  
John J. Moosy, MD  
Ian F. Pollack, MD  
Robert Sclabassi, MD, PhD  
William Welch, MD  
Howard Yonas, MD  
(Vice Chairman, Academic Affairs)

**Associate Professors**

Jeffrey Balzer, PhD  
Michael Horowitz, MD  
Larry W. Jenkins, PhD  
Amin Kassam, MD  
Mingui Sun, PhD  
Harold B. Weiss, MS, MPH, PhD

**Assistant Professors**

David Bissonette, PA-C, MBA  
(Assistant Chairman/Executive Director)  
Eleanor Carson-Walter, PhD  
Donald J. Crammond, PhD  
Anthony Fabio, PhD  
Peter Gerszten, MD, MPH  
Glenn Gobbel, DVM, PhD  
Ann H. Maitz, MSc  
Hideho Okada, MD, PhD  
Kevin Walter, MD

**Clinical Professors**

Joseph C. Maroon, MD  
(Vice Chairman, CMI Division)  
Peter Sheptak, MD  
(Vice Chairman, Clinical Affairs)

**Clinical Associate Professors**

Adnan A. Abla, MD  
Matt El-Kadi, MD, PhD  
Daniel A. Wecht, MD

**Clinical Assistant Professor**

Ghassan K. Bejjani, MD  
Michael J. Rutigliano, MD, MBA

**Research Professor**

Edwin Nemoto, PhD

**Research Assistant Professors**

Ajay Niranjani, MCh  
Ronda Pindzola, PhD

**Research Instructor**

Wendy Fellows-Mayle, MA

**Clinical Associates**

Eric Altschuler, MD  
Michael Moncman, MD  
David Zorub, MD

**Clinical Instructor**

Richard Spiro, MD

**Research Associates**

Yue-Fang Chang, PhD  
Xiecheng Ma, MD

**Visiting Fellows/Research Associates**

Manabu Hatano, MD  
Juan José Martin, MD  
Kotaro Nakaya, MD  
Daniel Prekumar, PhD  
Hulya Sirin, MD  
Sait Sirin, MD  
Margaret S. Wilson, PhD  
Hong Qu Yan, PhD

## The case of the numb thumb

In John Bunyan's classic allegorical tale, *The Pilgrim's Progress*, the pilgrim's ventures eventually lead him to a site called the Slough of Despond. One can imagine a black bog that the pilgrim descends into, perhaps analogous to the black depressions of a unipolar depressive disorder. I believe we physicians are approaching this slough of despond, as we are consumed by regulation, micromanagement, bureaucracy, meddling, and worst of all, the worsening malpractice climate. Pennsylvania may be one of the worst malpractice states with no hope in sight for tort reform, and no likelihood of state or federal legislation revamping this frightfully broken system. Sub-specialty physicians are difficult to recruit, many are fleeing from the slough. Let me give you a recent brief vignette.

Fortunately, by hook or by crook, I have escaped testifying in a medical malpractice action for 29 years. Those cases that I have agreed to provide review and testimony in are few, and geared towards the defense. My record was impeccable, since no case that I was reviewing had ever come to trial. I had never been in a court of law. My assessment: Bunyan's pilgrim meets Frans Kafka.

I came away from this experience congratulating our specialty that even if we are not perfect, if we ran a practice the way trial lawyers for the plaintiffs and the defense run a trial, we would all be run out of town on a rail. The case represented a potential unique twist on the current malpractice climate. Two trials were in process at the same time. One, a seemingly obscure allegation that a respected and well-educated surgeon with extensive experience preferred one surgical incision versus another, perhaps more standard incision. The patient alleged that he suffered an injury because of the exposure relating to this, leading him to have a minor bit of sensory dysfunction in one thumb, unable to work at his prior job, although his company went out of business. The plaintiff's lawyers wanted \$1.5 million. A second parallel allegation was made against the hospital, stating



that the institution was negligent because at the time of re-certification of this physician, they had not specifically restricted that physician from using the incision with which he was comfortable after more than 200 prior case experiences. A former hospital administrator (who had not actually been involved in a medical center in 20 years, and who charges approximately \$500 per hour for his legal testimony) gave a video deposition. He stated the hospital was categorically negligent in failing to restrict this surgeon's technique simply because at the time of re-certification, a *single allegation* had been made in a similar case against that physician.

At the time of the re-certification process, the case simply represented a writ, no trial, and no judgment (ultimately settled for a small amount) was complete. The plaintiff's lawyer subpoenaed me to be a witness of fact relative to the credentialing process of the institution.

On the stand, however, the plaintiff's lawyer attempted to use me as an expert witness, ostensibly against the defendant neurosurgeon, a former colleague. Of course, I testified that this surgeon had extensive experience, and to the best of my knowledge had no significant problems related to his surgical approach which was, in fact, used and taught by many centers, and which certainly did not violate the standard of care. The plaintiff's lawyer continued to have me read in examples of "the literature," mostly opinion pieces in non-peer reviewed book chapters, stating that the approach used was "widely condemned."

Did I support the re-credentialing of surgeons who used widely condemned procedures? Of course not. However, do plaintiffs' lawyers and their patients set the standard of care? Will our specialties always be able to provide the appropriate neurosurgical pimps who state opinions as if they represented the standard of care?

Can you imagine the implications if every plaintiff's complaint could include a dual charge,

(See *Thumb* on page 8)

# CyberKnife Radiosurgery for Spinal Lesions

by Peter C. Gerszten, MD, MPH  
*CyberKnife Program Director*

**S**tereotactic radiosurgery for brain tumors is a well-established technique. Its precision is unparalleled. Until recently, the use of this powerful tool has been confined to the treatment of lesions within the skull. Standard treatment for spinal tumors include radiotherapy alone, radionuclide therapy, radiotherapy plus systemic chemotherapy, hormonal therapy, or surgical decompression and/or stabilization followed by radiotherapy. The role of radiation therapy in the treatment of tumors the spine has been well established. A primary factor that limits radiation dose with conventional radiotherapy is the low tolerance of the spinal cord to radiation. Conventional external beam radiotherapy lacks the precision to allow delivery of large doses of radiation near radiosensitive structures such as the spinal cord. If the radiation dose could be confined more precisely to the treatment volume, as is the case for intracranial radiosurgery, the likelihood of successful tumor control should increase at the same time that the risk of spinal cord injury is minimized.

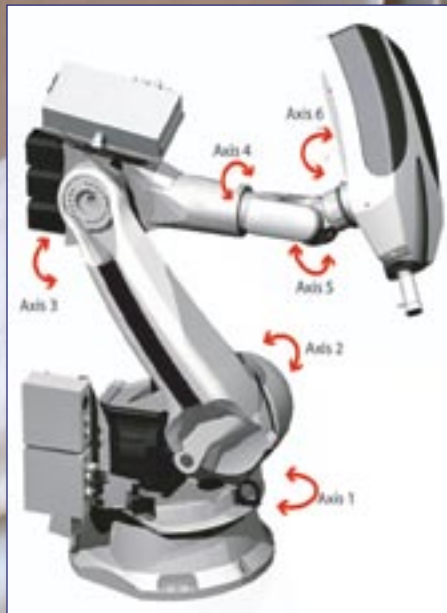
Stereotactic radiosurgery now has a feasible delivery mechanism using an image-guided frameless stereotactic radiosurgery delivery system known as the CyberKnife (Accuray, Inc., Sunnyvale, CA). The University of Pittsburgh Medical Center has pioneered the use of the CyberKnife for the treatment of spinal radiosurgery and has the single largest experience in the world. The CyberKnife system consists of a lightweight linear accelerator mounted on a robotic arm. It differs from conventional frame-based

radiosurgery in three fundamental ways. First, it references the position of the treatment target to internal radiographic features such as the skull or implanted fiducials rather than a frame. Second, it uses real-time x-ray imaging to establish the position of the lesion during treatment and then dynamically brings the radiation beam into alignment with the observed position of the treatment target. Third, it aims each beam independently, without a fixed isocenter. Changes in patient position during treatment are compensated for by adapted beam pointing rather than controlled thru rigid immobilization. This allows the patient to be positioned comfortably during the treatment without sedation.

The CyberKnife system utilizes image-guided frameless robotic radiosurgery. Two ceiling-mounted, diagnostic x-ray cameras are positioned orthogonally (90° offset) to acquire real-time images of the patient's internal anatomy during treatment. The images are processed automatically to identify radiographic features and are then registered to the treatment planning study to measure the position of the treatment site. The measured position is communicated through a real-time control loop to a robotic manipulator that aims a compact 6 MV linear accelerator. The system can adapt to changes in patient position during treatment by acquiring targeting images repeatedly and then adjusting the direction of the treatment beam.

The indications for spinal radiosurgery using the CyberKnife are currently evolving and will continue to evolve as clinical experience increases. We have treated over 400 spinal tumors with the CyberKnife. Candidate lesions may be of benign or malignant histology. Spinal vascular malformations are also amenable to spinal radiosurgery. Prior conventional external beam radiotherapy and/or surgery with or without instrumentation does not preclude spinal radiosurgery. Indeed, the majority of our patients have previously undergone either surgery or external beam irradiation. Over 90% of our patients have experienced improvement in pain following the procedure.

CyberKnife spinal radiosurgery has been found to be feasible, safe, and effective for the treatment of a wide variety of spinal lesions. The major potential benefits of radiosurgical ablation of spinal lesions are short treatment time in an outpatient setting with rapid recovery and good symptomatic response. This technique offers a successful therapeutic modality for the treatment of a variety of spinal lesions as a primary treatment or for lesions not amenable to open surgical techniques, and medically operable patients, lesions located in previously irradiated sites, and as an adjunct to surgery.



(Far left) The CyberKnife radiosurgery system. Note the two amorphous silicone x-ray screens positioned orthogonally to the treatment couch. The couch can move to position the fiducials in front of the cameras; (near left) the CyberKnife consists of a linear accelerator mounted on a 6-axis robotic manipulator that permits a wide range of beam orientations.

# Spinal instrumentation in oncology

by Kevin A. Walter, MD  
Assistant Professor of Neurosurgery

In the past, stabilization and instrumentation surgery was reserved for a select few patients with metastases to the bony spine. Surgeons and oncologists felt that aggressive surgical procedures were inappropriate in patients with such limited expected life spans and incompatible with the concept of palliative care. As cancer treatments have evolved over the last decade, surgeons have been forced to reassess these assumptions. As patients began to live longer with their spinal metastatic disease, the limitations of the widely used conservative treatment paradigms became evident. The bulky back braces prescribed to help with spinal stability were uncomfortable, reduced patient mobility, reduced quality of life and were used with poor compliance. The high doses of narcotics needed for even minimal pain relief in the setting of metastatic spinal instability generally rendered patients stuporous and lethargic. Finally, in the rare instances where surgery was employed it consisted only of decompressive laminectomy and was effective in relieving pain in less than 30% of patients.

We now understand that the failure of these early regimens was due to a misunderstanding of the mechanisms of a patient's pain. Spinal epidural metastases cause pain by three mechanisms. Firstly, tumor erosion through cortical bone surfaces of the spine deforms the bone covering or periosteum and inflames nerve endings. Secondly, tumor expansion can compress spinal nerves and produce radicular pain in a fashion similar to a herniated disc. Lastly, the significant bone erosion and loss of structural stability associated with metastatic disease results in abnormal movement and instability in the spine. While radiation

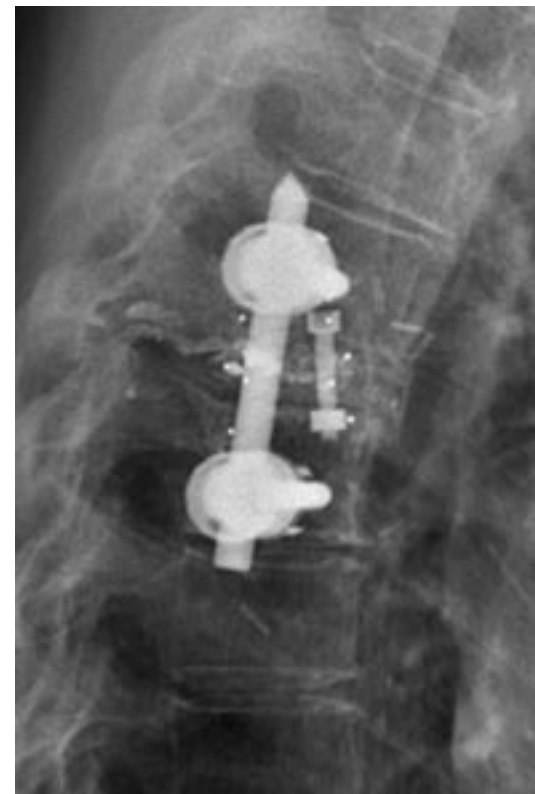
therapy effectively addresses periosteal pain and decompressive spinal surgery treats radicular pain, neither of these modalities improves or treats pain resulting from the loss of structural stability from bony metastases. In reality, decompressive laminectomy worsens spinal instability so it is not surprising that many patients treated with that modality alone sometimes report increased post-operative pain.

In an effort to address these failings, surgeons have turned to the wide variety of devices approved by the FDA for spinal fixation in degenerative spine disease and applied these techniques to spine oncology patients. These constructs are able to restore immediate stability to the spine, effectively replace bone eroded by tumor, preserve patient's mobility and function, and most importantly dramatically reduce patient pain.

## Patient Evaluation

Over 95% of patients with spinal epidural metastases will present to medical attention with a chief complaint of back pain. Generally this pain will have been present for approximately three months before the patient seeks medical attention for the problem. At that time the tumor growth will have progressed to cause either a neurologic deficit or spinal instability in about 40% of patients. Overall, up 20% of patients with certain types of metastatic cancer will experience spinal metastases at some point during the course of their disease.

Generally once a spine metastasis is suspected, a spine surgeon will ask for an MRI scan of the entire spine. Spinal MRIs are sensitive at finding even very small metastatic tumors. The images also show the relationship of tumor to the spinal cord and nerve roots. This information is critical in planning whether or not surgery is necessary for decompression. It also gives some hint as the degree of bony involvement occurring in the spine. Unlike the setting of degenerative spine disease where there is an excellent correlation between location of pain and location of spine pathology, pain in spinal metastatic disease is more diffuse. An MRI limited to a single area of the spine where pain seems to be greatest



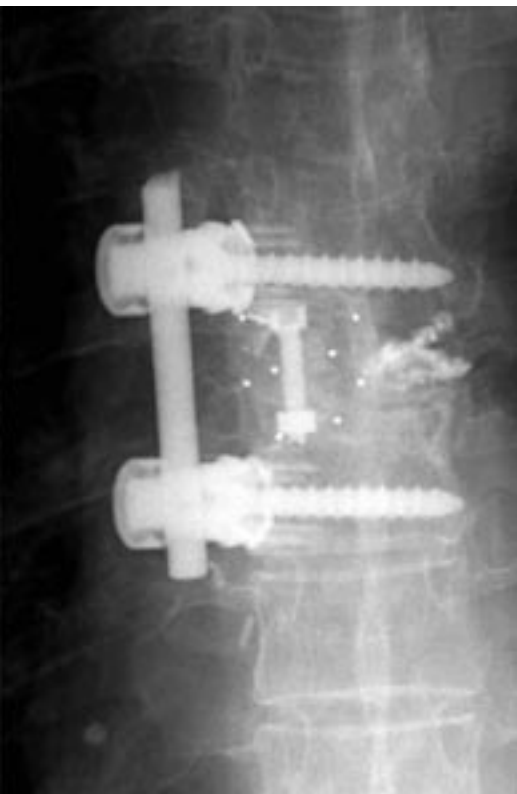
Anterior and lateral thoracic spine x-rays of a patient showing vertebral body stabilization with carbon fiber cages (below left) and on X-ray films. The small metal screw visible between them. The patient is alive, off narcotics, and in c

will often underestimate the amount of tumor involvement in the spine.

To make a full determination of bone erosion and spinal stability, however, an x-ray based imaging modality must be used. Three-dimensional CT Scans with sagittal and coronal reconstructions are optimal. Not only are they sensitive for bone erosion, they provide an excellent three-dimensional reconstruction of spinal anatomy alignment.

Other imaging modalities, such as flexion and extension radiographs may also be useful in limited cases to look for abnormal motion, but most patients who have significant spinal instability have too much pain to complete these exams. Similarly, nuclear medicine bone scans, while sensitive for initially detecting bony metastases in the spine, are not particularly helpful in planning surgical interventions due to their lack of resolution.

The primary goal of most spinal instrumentation surgery performed for metastatic cancer is pain reduction. In several large published series, an immediate and statistically significant reduction in pain was reported in >95% of patients undergoing spinal stabilization as measured by visual



...ent with multiple myeloma and collapse of the T6 ...ion. Patient underwent anterior tumor resection and ...l screw-rod fixation. The stackable cages are invisible ...een the T5 and T7 bodies holds the stackable cages ...omplete remission two-years post-operatively.

analog testing. These findings were supported by significant reductions in narcotic requirements. Unfortunately patients who present with complete paraplegia are unlikely to improve with surgery. In a very select group of patients who have an isolated spinal metastasis with no evidence of extraspinal disease or with certain isolated tumors such as an isolated plasmacytoma surgical resection with adjuvant therapy may be curative. These patients where surgery is performed with curative goal must be extensively evaluated pre and post-operatively. Even with the hope of curative resection, recurrence is common.

### Surgical Techniques

The approach to spinal reconstruction in patients with spinal epidural metastases can be performed via anterior or posterior approaches or both. Because spinal metastases occur with equal frequency in each of the vertebral bodies and the thoracic spine represents proportionally the largest section of the spine, thoracic metastases are most common. Generally metastases affect either the vertebral body or pedicle. Metastatic tumors confined to the lamina or posterior elements are less common. Therefore anterior

approaches to the thoracic spine are the most common operations that the spine oncology surgeon is asked to perform. The exposure is then in conjunction with a thoracic surgeon who assists with exposure of the chest and mobilization of the lung and if necessary mediastinal structures away from the spine. Once this approach is achieved the surgeon generally has an excellent view to remove tumor compressing the anterior spine as well as to reconstruct the spine afterwards.

More recently, a variety of cages have been developed which can be used to rebuild the anterior column of thoracic and lumbar spine. These cages can be packed with bone graft harvested either from the patient's hip or from a cadaver and can be cut or sized to custom fit the defect created by tumor removal. Because of the customizable nature of these grafts it makes them an optimal adjuvant for spine reconstruction in the setting of metastatic disease where the amount of spine to be replaced and reconstructed is quite variable. Among the best of the options for intraspinal reconstruction are stackable carbon fiber cages. These carbon fiber cages exist in a modular format and can be stacked one on top another to exactly fill the size of the defect left by the tumor. Because they are invisible on x-ray, they do not interfere with postoperative imaging to assess fusion rate and evaluation of tumor regrowth postoperatively. They also provide excellent structural stability to the spine immediately postoperatively and have an ability to withstand loads several times greater than that of the normal bone that they are replacing.

Anterior interbody fusion devices are further supplemented with additional stabilization devices. Anterior, thoracic and lumbar plates and/or screw rod fixation systems can be easily placed at the time of surgical decompression and interbody fusion cage placement. The anterior rods compress and stabilize the interbody graft between the superior and inferior vertebral bodies to prevent migration of the cage and improve construct stability. Augmenting the fusion construct using these maneuvers frequently makes additional surgery via posterior approach unnecessary.

While the majority of spinal metastases occur anteriorly, posterior metastases to the lamina or posterior elements do occur. Additionally metastases that arise from anterior vertebral body may grow through the pedicle to invade the posterior elements secondarily. In these instances remove of the tumor via

a posterior approach is generally indicated. At that time instrumentation to stabilize the spine to prevent further collapse and kyphosis is performed. While pedicle screw fixation, sublaminar hook fixation and sublaminar wire fixation have all been used in this disease setting, biomechanical studies have indicated that the rigidity and stability of pedicle screw fixation is several times better than that of hook based or wire based systems. In the setting of metastatic disease where the major goals is pain reduction via restoration of immediate stability, pedicle screws have clearly become state of the art.

Because a variety of pedicle screw width and sizes are now available, it's possible to place pedicle screws anywhere in the thoracic or lumbar spine. Similarly pedicle screw constructs can be joined with tapered rods to cervical constructs using lateral mass fixation. Because spinal metastatic tumors will often affect multiple levels of the spine the segmental nature of pedicle screw systems makes them an optimal choice for stabilization across multiple levels.

In rare instances patients will need to undergo a combination of procedures via an anterior and posterior approach. In these cases anterior decompression and stabilization is performed initially since this is the origin of compression of the majority of patients. Posterior decompression fusion proceeds as a second procedure or occurs at a later date once the patient has recovered from the first operation. In certain patients a posterior approach can be used effectively to perform both posterior and anterior stabilization. This is accomplished by resecting the tumor from the posterior using a transpedicular route to the anterior vertebral body. The anterior body is reconstructed with methyl methacrylate injected posteriorly through the defect and posterior stabilization is then performed using pedicle screw rods. This combined technique is particularly appropriate for the upper thoracic spine which can be challenging to access through a thoracic incision.

### Outcomes

In several prospective trials of spinal stabilization for metastatic disease there has been near uniform improvement in pain scores and quality of life for patients postoperatively. The old assumptions that surgery would be too painful or too invasive for patients with metastatic disease have proven unfounded. When metastatic disease is first detected in the spine, a prompt evaluation of spinal stability is indicated. •

# Roles of Radiotherapy, Radiosurgery in Initial Management of Brain Metastases

**John C. Flickinger MD**

*Professor of Radiology Oncology and Neurological Surgery*

**Douglas Kondziolka MD**

*Professor of Neurological Surgery*

**L. Dade Lunsford MD**

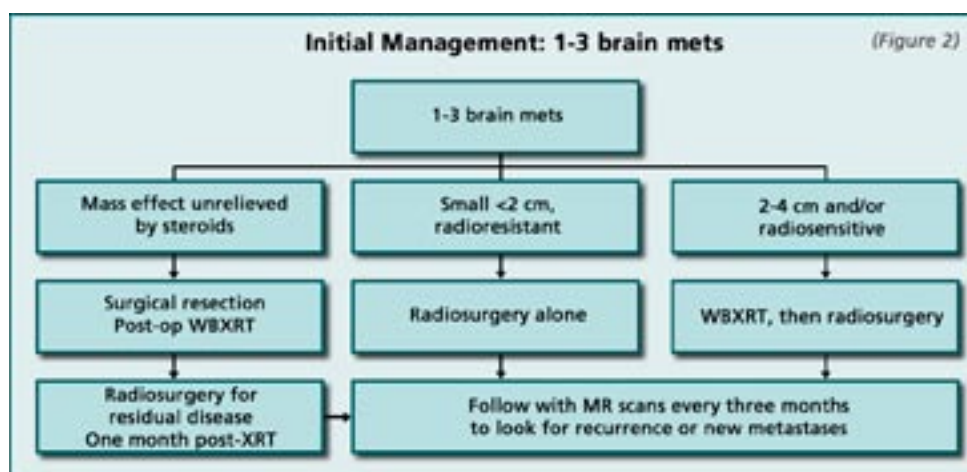
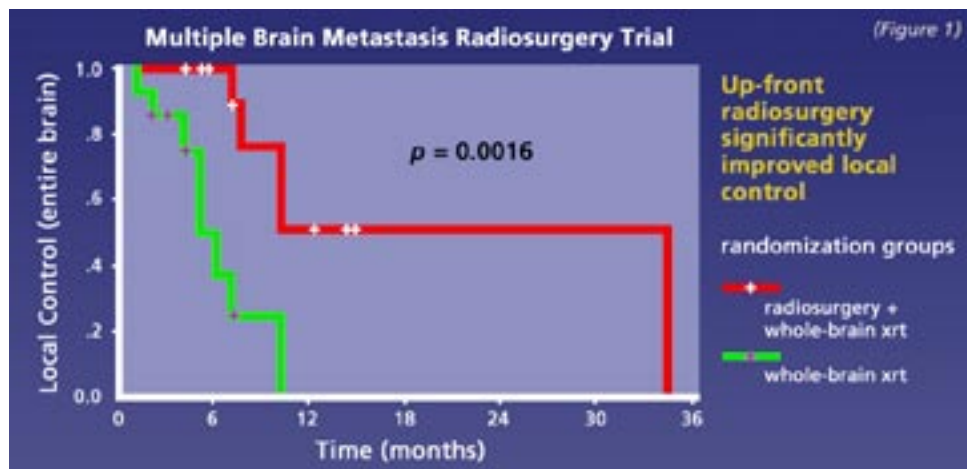
*Professor of Neurological Surgery*

Currently, brain metastases become apparent in 20% to 40% of cancer patients. As systemic therapy of cancer continues to improve and cancer patients live longer, this rate of metastases developing in a sanctuary site, like the central nervous system, should increase. Untreated brain metastases are associated with a survival of one month mostly because of central nervous system progression. Traditionally, whole-brain radiotherapy, (WBXRT), has been the standard of care for the treatment of patients with brain metastasis patients, yielding survivals of 3-6 months. WBXRT by itself is unreliable for long-term control of brain metastases. Two prospective, randomized trials in solitary brain metastasis patients showed that more aggressive local therapy with adding surgical resection to WBXRT improved survival.

Because of the advantages of radiosurgery (SRS) over surgical resection in terms of costs, hospitalization, morbidity, mortality, and wider applicability, SRS is being used more frequently to treat patients with brain metastases. A randomized University of Pittsburgh trial of adding radiosurgery to WBXRT in 27 patients with 2-4 brain metastases demonstrated dramatically improved local control for patients randomized to radiosurgery plus WBXRT compared to WBXRT alone (see figure 1).

Because of the use of salvage radiosurgery, a survival advantage was not proven. The Radiation Therapy and Oncology Group (RTOG) recently completed a large randomized trial of WBXRT with or without radiosurgery in 333 patients with one to three brain metastases <4cm in diameter, not involving brainstem. The addition of radiosurgery significantly improved local tumor control and survival in patients with solitary brain metastases (median survival 6.5 months vs. 4.9 months without radiosurgery). Radiosurgery patients were more likely to have stable or improved performance status at six months follow-up (43% vs. 27% without radiosurgery).

The guidelines for when to use radiosurgery, surgical resection, and whole brain



radiotherapy, alone or in combination are not clearly established. Patients with large, resectable, radioresistant brain metastases with mass effect symptoms unrelieved by steroids, limited systemic disease and no contraindications to surgery, will undoubtedly do better with surgical resection alone. Patients with multiple brain metastases from radiosensitive tumors, such as small cell lung cancer, are best managed with initial WBXRT, reserving radiosurgery for recurrence or failure. Patient with 1-2 small metastases from relatively radioresistant tumors such as melanoma or renal cell carcinoma are best managed with whole brain alone. Figure 2 shows a management pathway for brain metastases patients that integrates these modalities in the initial management of brain metastases.

Research efforts in the management of brain metastases at the University of Pittsburgh include participation in the American College of Surgeons Oncology Group study of radiosurgery versus WBXRT plus radiosurgery for brain metastases, the ongoing assessment of gamma knife radiosurgery for brain

metastases, the study of temozolomide plus whole brain radiotherapy in the management of brain metastases from non-small cell lung cancer, and preliminary work in developing a protocol to study using drugs with anti-angiogenic activity with radiosurgery alone to attempt to reduce subsequent seeding of new brain metastases. •

## Recent Donations

(All amounts: Up to \$1,000)

**Children's Neurosurgery Chair**  
United Way of Allegheny County

**Leksell Chair**  
Mr. & Mrs. Richard Dunn

**Peter E. Sheptak Chair**  
Burns, White & Hickton

**Peter J. Jannetta Chair**  
B.J. Morgan

**General Fund**  
Verla R. Chance  
Bettye Jo Haggard  
John Powers  
Roselynn Powers

### CIRCL Establishes Community Project Fund

The University of Pittsburgh's Center for Injury Research and Control (CIRCL) established a "Regional Community Initiated Project Fund" this past year and awarded \$8000 to three of Children's Hospital of Pittsburgh's Family Community Centers (FCC): Braddock/Rankin, Mt. Oliver, and Wilkinsburg.

Braddock/Rankin: "Home Safety for Kids," (\$3000). Help reduce home-based fall-related injuries and decrease reported and unreported trauma injuries to children.

Wilkinsburg: "Safe Home for Kids," (\$2500). Provide parents with usable items, education and follow-up to help prevent accidents in the home.

Mt. Oliver: "Bringing up Baby Safely," (\$2500). Assist parents in adapting their homes in order to provide a safer environment as their child's skills & mobility develop.

The objectives of this fund are 1) to augment newer efforts in injury prevention and control, 2) to provide a systematic means to translate research into community action, and 3) to provide outreach to the underserved communities within the region. Preference was given to proposals that focused on women and children with an emphasis on brain and spinal cord injury prevention and/or rehabilitation.

### CIRCL Successfully Completes Center for Disease Control Site Visit

The Center for Injury Research and Control successfully completed their Center for Disease Control Site visit on September 14-15. The agenda included special presentations on Dental Trauma, Neuromuscular Research at the Center for Sports Medicine, Traumatic Brain Injury, Inflicted Head Trauma in Infants, Neuroendocrine Hormones on Pathophysiology & Outcomes after TBI, and Traumatic Brain Injury CSF & Serum Banks.

### Research

- "Vaccination with glioma associated antigen peptides in NF1 and TRP53 mutant mice that develop spontaneous glioblastoma." **Hideho Okada, MD, PhD**, National Brain Tumor Foundation (\$15,000).

### Announcements

- **Peter C. Gerstzen, MD**, was a guest lecturer at the Annual Meeting of the Taiwan Neurospinal Society in Kaohsiung, Taiwan on July 23. His lecture was on radiosurgery for spinal tumors. Dr. Gerszten was also a visiting professor at the University of Virginia, September 7-8.

- **L. Dade Lunsford, MD**, served as visiting professor at Michigan State University in Lansing, MI, September 8-9.

- **Douglas Kondziolka, MD** served as visiting professor at the Mayo Clinic in Rochester, MN, September 16-17.

### Welcome and Transition

- **April Engram**, research assistant to Ian Pollack, MD; **Kim Hairston**, medical records coordinator; **Patricia Quirin**, CIRCL administrator, **Judith Kay Tisdale**, transcriptionist to Drs. Kondziolka and Lunsford; **Valerie J. Tattershall**, medical transcriptionist, **Jocelyn A. Bulger**, administrative assistant to William Welch, MD.

- **Jocelyn Koessler** is now senior administrative assistant to Howard Yonas, MD.

### Visitors

- **Steve Haines, MD**, professor and chairman of the Department of Neurological Surgery at the University of Minnesota served as visiting professor here September 9.

- **Mitchel S. Berger, MD**, professor and chairman of the Department of Neurological Surgery at the University of California, San Francisco served as visiting professor here September 22.

### Congratulations

- Baby boy (Nickhil, July 1) to **Ajay Niranjana** and wife Ranjana.

- **Rhonda Pindzola, PhD**, received a MPH degree from the University of Pittsburgh's Graduate School of Public Health in August.

### Endowed Chairs

The Department of Neurological Surgery currently has four endowed chairs at the University of Pittsburgh providing unique sources of support to individuals who have achieved prominence relative to patient care, research and teaching.

The four chairs and their holders are the Lars Leksell Chair (Dr. Lunsford), The Walter Dandy Chair, (Dr. Pollack), The Peter J. Jannetta Chair (Dr. Yonas) and the Children's Neurosurgery Chair (Dr. A. Leland Albright.)

A campaign is currently underway to fund a fifth chair, the Peter E. Sheptak Chair. This chair, honoring the career of the department's current vice chairman of clinical affairs, will help promote the career of a next generation neurosurgeon. Dr. Sheptak has performed over 50 years of clinical work related to spinal degenerative disorders, cerebrovascular disease and brain tumors.

For more information on any of these endowed chairs, please contact Wendy Edwards at (412) 647-0990 or Michelle Leive at (412) 647-7781.

### Upcoming Events

- November 7-9: **Stereotactic Neurosurgery In Your Practice Training Course**. Two-day training course designed for neurosurgeons and their staff with an interest in growing their practice in neuro-oncology and functional neurosurgery. The course will be held at the Four Seasons Hotel in Las Vegas, NV. Contact Kristie Maple at (412) 647-9539 for more information.

- November 15-19: **Principles and Practice of Gamma Knife Radiosurgery**. Training course targeted at neurosurgeons, radiation oncologists and medical physicists interested in Gamma Knife radiosurgery certification. The next course date is scheduled for January 10-14, 2005. Contact Charlene Baker at (412) 647-6250 for more information.

- January 7-8: **Minimally Invasive Endoscopic Surgery of the Cranial Base and Pituitary Fossa Course**. Series of lectures discussing approaches for endoscopic surgery of the cranial base and pituitary fossa. Experts on the subject will present technical aspects of those operations along with risks, benefits and outcomes. Live cases are included. Contact Melissa Hawthorne at (412) 647-6358 for more information. •



Department of Neurological Surgery  
University of Pittsburgh  
UPMC Presbyterian/Suite B-400  
200 Lothrop Street  
Pittsburgh, PA 15213  
(412) 647-3685  
neuroinfo@upmc.edu

[www.neurosurgery.pitt.edu](http://www.neurosurgery.pitt.edu)



Patient Referrals  
(412) 647-3685



FALL 2004 • VOLUME 5, NUMBER 4

## Multi-specialty approach essential in cancer care

*(continued from page 1)*

for tumor markers such as carcinoembryonic antigen, fetal antigen 2, and prostate specific antigen. However, 16% to 35% of patients with brain metastasis at initial presentation will have no identifiable primary malignancy. Prevention of the development of brain metastases is a challenging task. Chemotherapy may be utilized to help control extracranial disease but does not appear to alter the rate of intracranial metastasis.

Radiosurgery is a minimal access surgical technique designed to produce a specific radiobiological effect within a sharply defined target volume. A high dose of radiation is delivered in a single session. At UPMC, three Gamma Knife units are used to provide brain radiosurgery. Patients are evaluated promptly and scheduled quickly for treatment. Local tumor control rates following radiosurgery appear to be equal or superior to those afforded by resection and superior to those after radiotherapy alone.

In the past, progression of intracranial brain metastases was often the cause of death. Radiosurgery offers effective local tumor control, stabilized or improved clinical symptomatology, and enhanced survival. All of these radiosurgical goals are generally achieved with low morbidity, low cost, and essentially zero mortality. Extracranial disease progression is now more often the cause of death. Such findings underscore the therapeutic advances made in neurosurgery for treating patients with metastatic disease. Craniotomy and surgical resection has generally been reserved for patients with large, solitary, accessible and symptomatic brain tumors. Fewer than 30% of patients with brain metastases are eligible for surgery. Because of the need for irradiation following resection, and the delay inherent in restarting chemotherapy or immunotherapy, the decision to resect a tumor should be made wisely, and with the understanding that additional cancer care may be deferred. •

Non-Profit  
Organization  
U.S. Postage  
**PAID**  
Permit #4166  
Pittsburgh, PA

### CHAIRMAN'S LETTER

## Case of the numb thumb

*(continued from page 2)*

i.e. malpractice of the physician and negligence on the part of the institution for the credentialing process, specifically denying privileges to do certain procedures in certain ways because of a few opinions in book chapters? The potential for such a precedent is mind-boggling. Final judgment: \$680,000 for the plaintiff in the case of the numb thumb.

How did we physicians let ourselves come to this point? We are taught in medical school and in the years of our initial practice to build hope and trust, to hone our skills and to providing the best care possible. Did we know that we were going to spend our lives practicing defensive medicine, practicing CYA, and spending our time in courts while both the plaintiffs and defense legal teams play the lottery?

The tort system is inalterably broken. I suspect that only a concerted job action will help to restore balance in the system. In the meantime, I propose that the trial lawyers be restricted to simply suing each other. We can go on taking care of patients without them. •

**L. Dade Lunsford, MD**

*Lars Leksell Professor*

*Chairman, Department of Neurological Surgery*