



Next generation Gamma Knife technology coming to UPMC Presbyterian

The next generation of the world's leading gamma knife radiosurgical technology, the Leksell Perfexion® Gamma Knife, is scheduled for installation at UPMC Presbyterian's Center for Image-Guided Neurosurgery in the spring of 2007.

Redesigned from the ground up, the Perfexion system is a completely new system that takes stereotactic radiosurgery to the next level and provides a radiosurgical platform for further refinement and expansion of procedures in the brain, cervical spine and head & neck regions. The new system features advanced patient treatment and safety features including a newly remastered, more flexible dose delivery system allowing physicians to administer doses to all targets while the patient is still in the original treatment position. With this new technology, physicians can non-invasively treat multiple brain lesions simultaneously—in one single automated procedure, in one single day.

Gamma knife radiosurgery is used to treat numerous neurosurgical problems, including brain tumors such as metastatic cancer, some primary glial tumors, and also in the management of vascular malformations, acoustic neuromas, other skull base tumors. It is also utilized for chronic pain conditions including trigeminal neuralgia, movement disorders and epilepsy.

Gamma knife radiosurgery is used as primary management in some patients, or in other cases after prior partial removal of symptomatic tumors through innovative approaches including endoscopic skull base surgery. Long term outcome studies have defined the role of radiosurgery, and led to its incorporation in many major medical centers.

Approximately 10% of all brain surgery performed in the United States is done with some radiosurgical technique. The Gamma Knife represents a state-of-the-art technology which is able to provide the highest level of 3-D volume shaping for a single procedure treatment using precise guiding technologies. Patients are treated on an outpatient basis. Complication risks are low and tumor control rates range from 93 to 99% as evaluated by

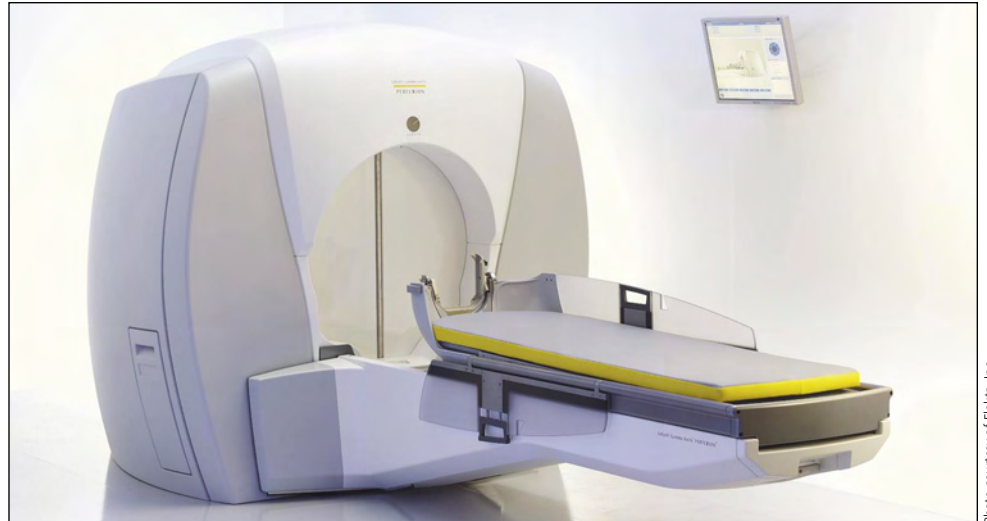


Photo courtesy of Elekta, Inc.

Next generation Leksell Perfexion® Gamma Knife unit set for installation at UPMC Presbyterian.

long-term outcome studies at the University of Pittsburgh.

The Center for Image-Guided Neurosurgery at the University of Pittsburgh—under the direction of L. Dade Lunsford, MD, and Douglas Kondziolka, MD—has shaped the development of gamma knife radiosurgery for over 19 years. The first U.S. 201 Cobalt-60 source Leksell gamma knife was installed at UPMC Presbyterian in August 1987. Since that time, Drs. Lunsford and Kondziolka, have partnered with a team of radiation oncologists and medical physicists to provide treatment to more than 8,000 patients.

The UPMC program has resulted in more than 300 peer-reviewed academic publications, several books, and more than 100 book chapters defining the benefits of radiosurgery. The program has also assisted in the training of most of the neurosurgical, radiation oncology and medical physicist practitioners of gamma knife radiosurgery in the United States, sponsoring over 55 one-week courses in the field of radiosurgery during the last ten years.

Five years ago, Drs. Lunsford and Kondziolka, were asked to serve on an advisory panel of the manufacturer of the gamma knife, Elekta, Inc. Working with other surgeons, radiation oncologists, physicists,

and engineers, Elekta decided to re-design the latest generation gamma knife from the bottom up. The goal was to expand treatment options, improve treatment efficiencies, and to maximize the usage of robotics. The first new generation Leksell Gamma Knife Perfexion was installed in Marseille, France in the summer of 2007. Dr. Lunsford helped celebrate the installation of this device by providing the inauguration lecture in Marseille in a special ceremony attended by hospital, city, and provincial leaders.

UPMC currently has three gamma knife units in operation—the original gamma knife U unit, currently used for radiobiological research, and two 4C robotic models. As was the case with each of these three units, the Perfexion Gamma Knife at UPMC will be the first unit of its kind installed in the United States.

UPMC and Elekta have partnered in the assessment and use of a variety of technologies over the last 25 years, including stereotactic guiding technologies, robotic surgical microscopes, magnetoencephalography, linear accelerator radiation systems, and gamma knife radiosurgery. This partnership has been enormously beneficial to thousands of patients who previously would have to undergo other more invasive surgical procedures or radiation treatment. •

Professors

P. David Adelson, MD
(Vice Chairman, Research)
C. Edward Dixon, PhD
Douglas Kondziolka, MD, MSc
(Vice Chairman, Education)
L. Dade Lunsford, MD
John J. Moosy, MD
Ian F. Pollack, MD
Robert Sclabassi, MD, PhD
William Welch, MD

Associate Professors

Jeffrey Balzer, PhD
Peter Gerszten, MD, MPH
Michael Horowitz, MD
Larry W. Jenkins, PhD
Amin Kassam, MD
(Interim Chairman)
Ajay Niranjani, MD
Mingui Sun, PhD
Harold B. Weiss, MS, MPH, PhD

Assistant Professors

David Bissonette, PA-C, MBA
(Assistant Chairman/Executive Director)
Boyle Cheng, PhD, ScD
Donald J. Crammond, PhD
Anthony Fabio, PhD
Glenn Gobbel, DVM, PhD
Paola Grandi, PhD
Miguel Habeych, MD, PhD
Costas Hadjipanayis, MD, PhD
Ann H. Maitz, MSc
Arlan Mintz, MD, MSc
Hideho Okada, MD, PhD
David O. Okonkwo, MD, PhD
Richard Spiro, MD
Elizabeth Tyler-Kabara, MD, PhD

Clinical Professors

Adnan A. Abba, MD
Matt El-Kadi, MD, PhD
Joseph C. Maroon, MD
(Vice Chairman, CMI Division)
Peter Sheptak, MD
(Vice Chairman, Clinical Affairs)

Clinical Associate Professors

Jadish P. Bhatnagar, ScD, FACR
Daniel A. Wecht, MD

Clinical Assistant Professors

Michael J. Rutigliano, MD, MBA
Naman A. Salibi, MD, MSc
Theodore J. Spinks, MD
Matthew Wetzel, MD

Research Assistant Professors

Wendy Fellows-Mayle, MA
Hong Qu Yan, MD, PhD

Clinical Instructors

Jeff Bost, PA-C
Daniel Prevedello, MD
Theodore J. Spinks, MD
Ajith Thomas, MD

Research Associates

Yue-Fang Chang, PhD
Xiecheng Ma, MD

Visiting Research Associate

Easter P. Jane, PhD

Chief Residents

Pedro J. Aguilar, MD
Joseph G. Ong, MD
Michael Sharts, MD

2025: How do we prepare?

Every January the most important academic task that we face at the University of Pittsburgh is selection of the next group of residents to train within our neurosurgery program. One would think that the overriding consideration in choosing these individuals is to identify those with the greatest intellect. In this regard the work is done for us. One hundred and seventy five individuals apply for an interview and the 15-20 medical students that are placed on our rank list all have board scores in the 99th percentile, 4.0 college GPAs, and all honors in medical school courses. What is not objectively measured, however, is heart and mind. The interview process' goal, therefore, is to determine as best we can which candidates are truly dedicated to studying and caring for the central and peripheral nervous system. It is also used to determine which individuals are open to new ideas and new concepts. Is the candidate enamored with currently performed procedures or is he/she attracted to nervous system disease and treatment no matter what the means?

For our program and the field of neurosurgery in general, the latter question is of key importance. The University of Pittsburgh's Department of Neurosurgery has always made its mission the development of new, more effective, and at times less invasive methods of treating neurologic disease. The concepts and practice of microvascular decompression, skull base surgery, stereotactic and radiosurgery, endovascular surgery, and endoscopic surgery have all been embraced within our institution years ahead of their acceptance into the neurosurgical mainstream. As it relates to resident training this mission necessitates the attraction of young medical school graduates who are open to new ideas and prepared to learn the practice of future procedures today. It is not acceptable to train residents that will graduate perfectly performing procedures

used in the 1990s or early 2000s when they will be treating patients on their own in the mid-2000s. While we are accepting individuals now who will graduate from our program in 2015 we must prepare them to practice in 2025 and must ensure that this class of residency graduates will look ahead and develop those procedures that will be used in 2050.

In order for us to prepare residents for neurosurgery of the future, we must have a clear understanding of what it will look like. It is our opinion that the practice of neurosurgery in 2025 will be a combination of the tried and tested principles of neurosurgery that have survived decades such as those of microsurgery. These principles will be blended with evolving trends and innovations featuring aspects of subspecialization with a particular emphasis on minimally invasive approaches. This paradigm has already occurred within general surgery. However, it is important to note that the underlying fundamental tenets and principles of neurosurgery will always survive and must be embraced, encouraged and perpetuated.

As we once again submit our match list and wait to hear who our next group of residents will be, we remain confident that those that have been offered one of the three seven year neurosurgical training positions within our institution will graduate in 2015 prepared for 2025. Even more importantly, however, is that each of these individuals will carry on our program's tradition of looking ten years into the future so that they are never satisfied with practicing current procedures to perfection but rather, are driven to developing and performing future procedures to perfection today. •



Amin Kassam
Interim Chairman
Department of Neurological Surgery

Baby's brain repaired with innovative medical procedure

By Anita Srikameswaran
Pittsburgh Post-Gazette

The innovative repair of a rare blood vessel malformation in his brain allowed one-year-old Kade Casteel to celebrate Christmas for the first time with his older sisters at home near Baton Rouge, LA.

His father, John, told Dr. Michael Horowitz, director of neuroendovascular surgery at the University of Pittsburgh Medical Center, "You gave us the best Christmas present anyone could. You gave us a healthy child we can take home."

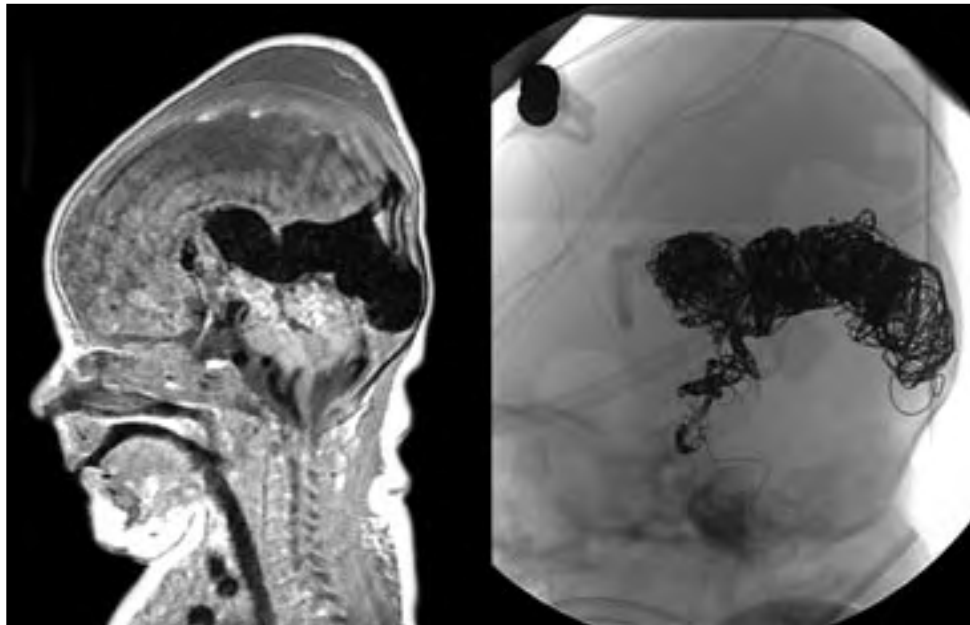
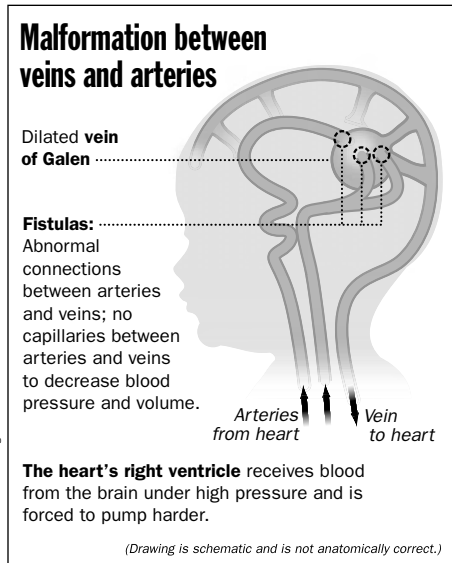
Last year, Kade spent the holidays at Children's Hospital, recovering from initial treatment of the congenital abnormality that had pushed his heart to the brink of failing.

His story begins with his birth on Nov. 29, 2005. For the first three days, he appeared to be fine.

"On the fourth day, when I was on my way to pick him up and bring him home, the pediatrician listened to his heart and didn't like what he heard," his father said. A cardiologist was brought in.

The doctors discovered that the pressure in Kade's lungs was too high, and they began treating him for primary pulmonary hypertension. But after five days, the baby was no better. He was transferred to a pediatric hospital in New Orleans for further treatment.

After six days, Mr. Casteel said, Kade's brain was scanned as a routine precursor to an intervention called extracorporeal membrane oxygenation, or ECMO, which doctors were considering to support the boy's weakened heart and lung function.



(left) MRI scan showing large dilated vein; (right) xray of head following embolization with platinum coils in malformation.

The brain scan revealed the real problem: Kade had what is called a vein of Galen arteriovenous malformation. The arteries were abnormally connected to the veins, with no capillaries between them to reduce blood pressure and volume. Blood returned to the heart under high pressure, forcing the pump to work harder and harder to meet the unending demand from the brain vessels.

As Dr. Horowitz would later explain, "It's like trying to empty out a sink, and as you're emptying the sink, somebody is pouring more water in. Eventually you get tired of emptying it and it overflows."

Kade's heart was failing under the strain. His parents were told it was likely the baby had already suffered brain damage and nothing more could be done.

"That just scared the daylights out of us," Mr. Casteel said. "When a doctor tells you to prepare for your baby to die, that's not something you want to hear, especially when he's two weeks old."

The worried dad called his own mother, a hospital administrator in Lafayette, La. She called a neurosurgeon in New Orleans who suggested contacting Children's Hospital in Pittsburgh. Children's, in turn, referred the family to Dr. Horowitz, who treats perhaps one or two youngsters for the condition each year.

The condition occurs in fewer than one out of 100,000 people, he estimated.

Kade was flown here by medical helicopter. Once here, critical care experts worked carefully to stabilize him. At one point, he had seven pumps pushing medicines into him to keep him alive, his dad said.

In a procedure that he repeated daily for the next several days, Dr. Horowitz guided special catheters through the blood vessels in Kade's groin up to the vein of Galen malformation in his brain.

He deposited hundreds of platinum coils into it with the aim of creating resistance to the torrent of blood flowing through the abnormal connections.

"We put a Mercedes in his head for what those coils cost," Dr. Horowitz wryly noted. With time, Kade's doctors hoped, scarring would further close off the connection. And, instead of taking the path of least resistance, blood would flow more readily to other parts of the brain.

The procedures eased the considerable burden on Kade's heart, and he was weaned off the ventilator that had been assisting his breathing. In mid-January, he was transferred to the Lafayette hospital, where his grandmother works, to continue gaining strength.

Kade was home by the time he was three months old, and he continued to develop normally. He smiled, crawled, stood

(see *Innovative* on page 6)

Paleopathology findings provide insight into disease, treatment

by Peter C. Gerszten, MD, MPH
Associate Professor

Although the study of ancient human remains may bring the immediate impression of a simple look into the past, a closer look into the findings uncovered in the field of paleopathology could provide substantive yields in our understandings of disease and treatments.

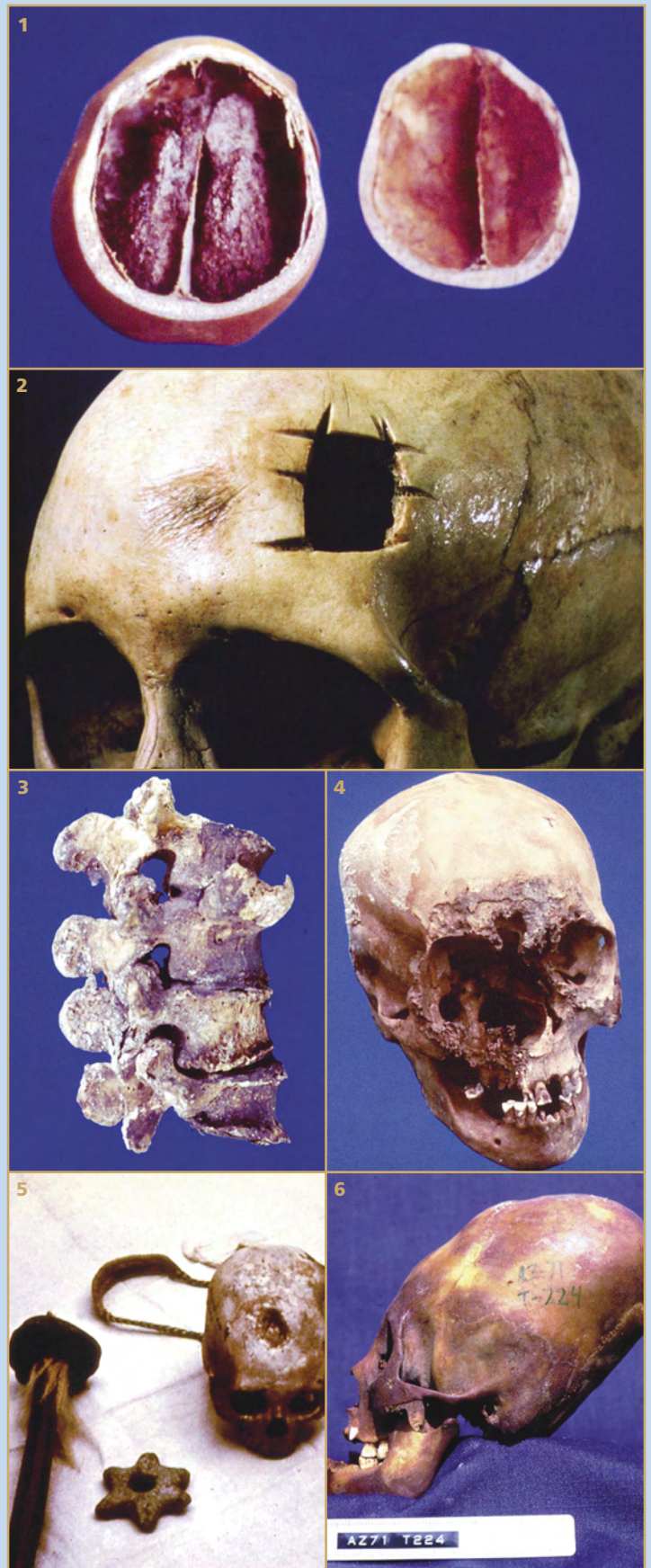
The term paleopathology refers to the study of diseases of antiquity in human and animal remains. The father of paleopathology is considered to be Sir Marc Armand Ruffer, an Englishman, who coined the term in the early 20th Century. Most early paleopathologists were physical anthropologists who had to rely mainly on skeletal material for their investigations because of its better preservation. Well-preserved soft tissue remains are usually difficult to obtain. My interest in the field of paleopathology began during my studies as an undergraduate student at the University of Virginia in the Department of Anthropology, inspired by my father's (Enrique) work of over 40 years in the Department of Pathology at the Medical College of Virginia Campus of Virginia Commonwealth University studying the well-preserved human remains of mummies of Peru and Chile.

My first supported field work was in the Azapa Valley of northern Chile, in the city of Arica, at the University of Tarapaca, investigating the practice of intentional cranial deformation among the pre-Columbian peoples who inhabited the region for over 8,000 years. The practice of tightly binding and bandaging the heads of infant children in order that their skulls would grow into unique oblong shapes was almost universally practiced by these peoples until it was prohibited by the Spanish conquerors. This work was the first to demonstrate that head deforming yields significant information regarding the political and cultural changes that occurred throughout the prehistory of the region. Furthermore, specific pathological consequences that resulted from the practice were described, such as occipital bone necrosis and abnormal closing patterns of the cranial sutures.

The skull is the part of the human body most frequently recovered in archaeological excavations and is therefore the most studied part of the human skeleton. From studying the skull, a large amount of information can be obtained regarding the individual, such as sex, age, nutritional status, and other disease processes, if present. More than 700 skulls recovered from archaeological excavations from the Andean region of southern Peru and northern Chile dating back more than 8,000 years were examined. A variety of skull abnormalities were encountered, including congenital, environmental, traumatic, infectious, and neoplastic lesions. Two cases of craniosynostosis were encountered. Exostoses of the external auditory canal resulting from chronic ear infections were frequently encountered in populations known to have been shellfish diving in the cold Pacific waters. The practice of trephination was widespread among the pre-Columbian inhabitants of the Andean region. The incidence of traumatic calvarial injuries ranged from 7 and 13% depending upon the time period. Examples of both benign as well as malignant skull tumors were found.

The spinal column is also frequently found in a well-preserved state and can provide a large amount of information about the individuals' physical condition. Examples of congenital malformations, degenerative processes, infectious diseases, neoplasia, and traumatic diseases were encountered. Congenital processes such as spinal bifida occulta were relatively common in these populations. Cervical spondylosis was quite common as a result of the practice of carrying heavy loads on

(see *Paleopathology* on page 8)



(1) Mummified skull and brain; (2) trephination forehead cross cutting; (3) vertebral body arthritis; (4) lytic lesion of the face likely due to leishmaniasis; (5) fatal skull fracture produced by a sling stone (sling and star mace were buried with warrior); (6) intentionally elongated skull.

Everest Study looks at brain stimulation to give stroke recovery a boost

By Anita Srikameswaran
Pittsburgh Post-Gazette

Researchers are testing an experimental brain stimulator that promises to spark more recovery in arms and hands that have been weakened by strokes.

Dr. Douglas Kondziolka, professor of neurosurgery at the University of Pittsburgh Medical Center, is leading the local arm of the multicenter trial, known as the Everest Study.

After a stroke, the brain tries to build alternate pathways to restore function. "There's science that suggests low-level electrical stimulation facilitates that recovery," Dr. Kondziolka said.

The Everest trial, launched by medical device company Northstar Neuroscience

Inc., will focus on stroke survivors who have weakness in one arm or hand.

"Unfortunately many patients who've had a stroke end up with no arm function," Dr. Kondziolka said. "This is not truly for all patients. They should have some residual movement there that hopefully can be improved upon."

Joe Marchione, 74, of Hampton, will be the first participant in the local study.

"I'm very excited about it," he said. "I have always been adventuresome and I want things to improve, and this is one way of making improvements."

Four years ago, Mr. Marchione had just packed his car for a road trip to Maryland when a heart tumor he didn't know he had threw off a clot that lodged in a blood vessel in his brain, causing the stroke.

"I was in the hall and I found my way to the back room and lay down on the couch," he said. His wife, a nurse, "had no idea how I did that."

After the crisis, and the successful removal of the heart growth, Mr. Marchione began the rehabilitation process for his weakened right side.

"I had to learn how to walk all over again," he said. "I learned to walk and climb stairs and open cans and do those occupational things we all have to go through and do."

Mr. Marchione regained much function during the next six months, and now considers himself "very fortunate." But his right hand doesn't always do what he wants. His grip is strong and he can pick up small objects, he said, but his fingers no longer have their former dexterity.

"My writing is abysmal," he said. "It was never good to start

with, but it's really bad now. I used to be a rapid typer. Now I sort of hunt and peck."

In the Everest study, participants will be randomly assigned to either get a stimulator implanted in the brain or not. All will get six weeks of intensive hand and arm therapy. The stimulators will be turned on in those who have them during the sessions to deliver brief electrical impulses to the targeted area.

Mr. Marchione will know whether he has a stimulator or not, but he has to keep that a secret from the therapists and the rest of the medical team so their findings are not biased.

"I have to go to and from the hospital with a hood on," he said, laughing.

Participants will have a functional MRI to locate the area in the brain that controls hand movement, Dr. Kondziolka explained. In the operation, narrow strip electrodes are placed over that spot, sewn to the brain's protective covering.

The electrode cable is tunneled through the neck to a battery in the chest. Doctors wave a wand over it to give the stimulator commands.

"The patient feels nothing when the stimulator is on," Dr. Kondziolka said. "Later on, the device can be taken out."

Participants will be regularly reassessed so researchers can determine if the stimulator enhanced recovery.

According to Northstar Neuroscience data from previous studies, patients who had stimulation during therapy had a 15 percent to 30 percent improvement in tests of their hand and arm function, while those who didn't have a stimulator improved up to 12 percent.

For more information about the Everest study, call 1-888-546-9779 •

(Copyright, *Pittsburgh Post-Gazette*, 2006, all rights reserved. Reprinted with permission.)

(Left) Narrow strip electrodes are placed in the location of the brain known to control hand movement. The electrodes are connected to a battery-powered device implanted in the chest just below the collar bone. The stimulator is then activated by passing a special wand over the device sending a signal to the electrodes. Study participants will receive six weeks of intensive therapy in the Everest study as researchers attempt to determine if the stimulator can promote more recovery in hands and arms in stroke victims.

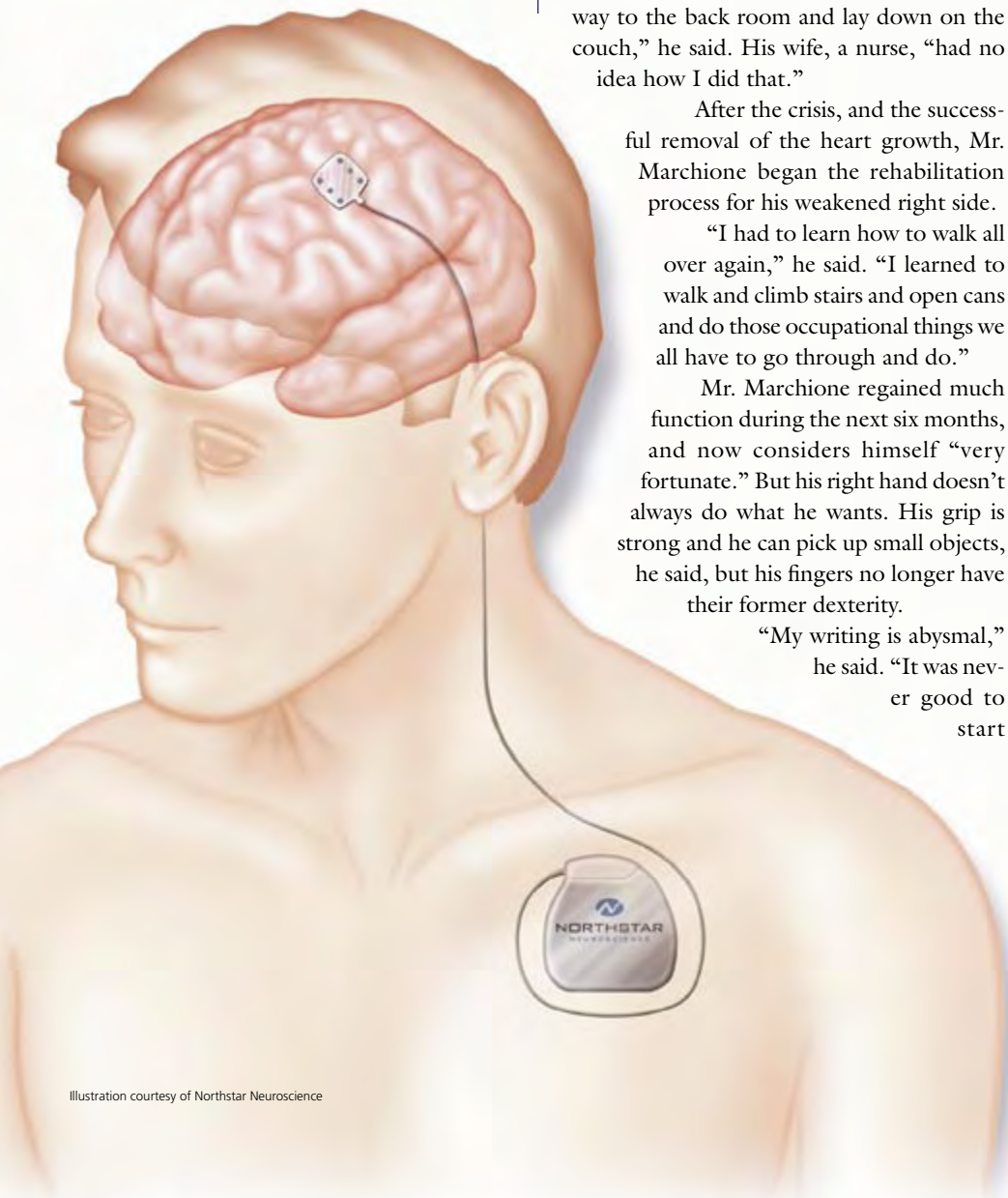


Illustration courtesy of Northstar Neuroscience

Innovative medical procedure utilized to repair baby's brain

(continued from page 3)

up, and took baby steps. His brain seems undamaged by the ordeal.

"He is a very happy-go-lucky baby," Mr. Casteel said. "Not much bothers him."

A couple of weeks ago, though, a cardiologist noted that Kade's heart rate was higher than usual. His father called Dr. Horowitz, who was concerned that Kade's heart might be working too hard again.

Within days, Kade was on his way back to Children's Hospital. Tests showed the malformation was still there, as Dr. Horowitz had expected it would be.

He recommended doing the coil insertion procedure again, but with a twist. He would also fill the vessels with a material, called Onyx, that turns from liquid into solid when it mixes with blood.

Dr. Horowitz had used it before to treat other kinds of arteriovenous malformations, but not for vein of Galen defects. Kade's parents decided to try it.

By the end of the procedure, the abnormal blood-flow pattern was gone, the doctor said. He added that Onyx might not have worked in this situation without the coils, which acted like rebar holding concrete together.

Still, Dr. Horowitz told Mr. Casteel at the time, "We've either hit a home run or he may get really, really sick."

For the next two days, Kade was watched closely for bleeding into his brain. But after a bout of pneumonia, he was clearly on the mend.

The boy will probably be 5 or 6 years old before Dr. Horowitz sees him again for a checkup, sooner if heart problems resurface. But the doctor doesn't expect that to happen because, he said, "I think it's completely treated right now."

Last week, the Casteels returned home, joining daughters Serena, who turns 4 in March, and Jordan, 2, who had been staying with their mother's parents.

The older girl explained it simply to her sister, who was upset while their parents were gone. She said, "Mommy and Daddy took Kade to Pittsburgh so he can get his head fixed. They'll come home when he's better." •

(Copyright, *Pittsburgh Post-Gazette*, 2006, all rights reserved. Reprinted with permission.)

Recent donations to the Department of Neurological Surgery

A. Leland Albright Chair

• Up to \$1,000:
United Way of Allegheny County

Peter J. Jannetta Chair

• Up to \$1,000:
B. J. Morgan

Gamma Knife

• \$1,000 - \$5,000:
Blase J. Pignotti, MD

• Up to \$1,000:
Elinor M. Abplanalp
Joyce A. Abraham
Tina Ann Barry
Jack C. Bendheim
Mr. & Mrs. Pat A. Buzzeo
Goldie M. Clark
Denver H. Collins
Patricia S. Dearth
Nancy M. Dunlap
Joan Evanoff
Robert Hagan
Paul T. Higgins
Ann B. Hittner
James D. Janes
Betty Karafa
James J. Kaufman
Mr. & Mrs. Joseph Klyde
Li-Ching Liang
Mr. & Mrs. Robert M. Miller
Doris May Nacey
Mr. & Mrs. Ronald M. Pomaranski
Wilma Ruskin
Mr. & Mrs. Otto N. Schiberl
Ellen M. Shreffler
Robert Sines
Mr. & Mrs. Delton M. Sinz
Loretta Stocks
Edith J. Swingle
George Trach
Mr. & Mrs. James M. Watt
Marilynn Weiss
Richard Leo Welsh, PhD
Patricia R. Wolfe
Cheng Dong Young, DMD

MINC Endovascular – Dr. Jovin

• \$1,000 - \$5,000:
Mr. & Mrs. Thomas R. George

• Up to \$1,000:
Mary Ann DeFigio
Suzanne L. Gilliland
Mr. & Mrs. John F. Krumwiede
Richard M. Larry
Mr. & Mrs. Matt Los
Dr. & Mrs. Bertrand L. Stolzer

MINC Research Development Fund

• \$5,000 - \$10,000:
Pamela K. Sagan

• Up to \$1,000:
J. Thomas Armstrong
Mr. & Mrs. Curtis W. Bicehouse
Richard W. Biddle
Mr. & Mrs. James R. Catlett
Min Chu
Dale M. Cushing
Grace R. Dickens
Mr. & Mrs. Robert H. Dodge
Rostyslaw Dowbenko
Mr. & Mrs. Russell C. Hildreth
Sharon P. Ickes
Judith A. Kindle
Mr. & Mrs. Jack G. Lunney
Pamela Miller
Elvira A. Morgan
Chris A. Muhr
Patricia Neish
Mr. & Mrs. Anastasios Panas
Mr. & Mrs. Dwight P. Plowman
Christine A. Rankin
John F. Rankin
Maria Lynn Sarti
Brady Shick
Dolores M. Sladewski
Jean Smith
Kathleen Stevens
T. J. Stevens
Jo Ann Throckmorton
Rebecca R. Troup
Elaine Varnecky
Mr. & Mrs. Gary Zentner

Neurotransplantation Fund

• Up to \$1,000:
Mr. & Mrs. John E. Kollek

Pediatric Neurosurgery – Dr. Pollack

• \$25,000 - \$50,000:
Saint Baldrick's Foundation

Peter E. Sheptak Chair

• \$1,000 - \$5,000:
Mr. & Mrs. Robert J. Brooks

• Up to \$1,000:
Mr. & Mrs. Bill Asnip Sr.

Welch Biomechanics Lab

• Up to \$1,000:
Lee A. Bastin
Dale M. Cushing
John W. Skooglund

Adelson Elected Congress Vice-President

Department vice-chair of research, **P. David Adelson, MD**, was recently elected to serve as vice president, of the Congress of Neurological Surgeons (CNS) beginning with the group's recent annual meeting in October. CNS is a leading international neurosurgical organization with a mission to promote public welfare through the advancement of neurosurgery, through a commitment to excellence in education, and by dedication to research and scientific knowledge.

Dr. Adelson also currently serves as chair of the AANS/CNS Joint Section on Neurotrauma and Critical Care and co-chair of the AANS/CNS Joint Guidelines Committee. He recently served as treasurer of the CNS.

Atteberry Lecture Selected Best at Rowe Lectureship

Sixth-year resident **Dave Atteberry, MD**, received the best presentation award at the second annual Department of Neurological Surgery Stuart Rowe Society Lectureship held on December 7. Atteberry's presentation on "A Comparison of Outcomes Between CyberKnife Radiosurgery and Conventional XRT for Spinal Metastases" was one of seven research lectures presented by department residents during the day honoring Stuart Niles Rowe, the department's first chairman and an early advocate of broad neurosurgical training. The award was chosen and presented by the lectureship's honored guest, M. Sean Grady, MD, Charles Harrison Frazier Professor and Chairman of Neurological Surgery at the University of Pennsylvania Health System.

In addition to the resident lectures, the day featured a lecture on the management of traumatic brain injury by Dr. Grady, a noted international expert in the field. Dr. Grady also presided over a journal club and later capped the day with an informal talk on academic neurosurgery after a reception and dinner at the Fox Chapel Golf Club.

Honor/Recognition

- The Congress of Neurological Surgeons announced that it has selected former department chairman **L. Dade Lunsford, MD**, as its honored guest for its 2007 annual meeting in San Diego, September 15-20.
- **Mingui Sun, PhD**, **Robert Sclabassi, MD, PhD**, and grad student **Steve Hackworth** received University of Pittsburgh Innovation Awards for their work on the project "Volume Conduction Communication Channels for Brain Implantable Devices."

Announcements

- **Elizabeth Tyler-Kabara, MD, PhD**, was granted a secondary faculty appointment as assistant professor in the Department of Bioengineering.
- **Costas Hadjipanayis, MD, PhD**, was granted a secondary faculty appointment as assistant professor in the Department of Molecular Genetics and Biochemistry
- The Think First for Kids program received \$80,000 through Children's Hospital of Pittsburgh from Kohl's Foundation for this fiscal year. **Dr. Adelson** is the organization's sponsoring physician. **Karen Zuri** is the project director and **Darius Carlins** is the program coordinator.

Prominent Lectures

- **Peter Gerszten, MD**, was a guest lecturer at the National Cancer Center of Brazil in Rio de Janeiro November 15-17, 2006. He was also a guest professor at the Mayo Clinic Department of Neurosurgery in Rochester, MN on December 5-6, 2006.
- **Dr. Lunsford** gave the inaugural address for the placement of the first Leksell Perflexion Gamma Knife in Marseille, France, September 15. Drs. Lunsford and Kondziolka served on the design team of this next generation Gamma Knife unit.
- **Douglas Kondziolka, MD**, was an invited lecturer at the French Speaking Radiosurgery Course in Marseille, France, November 6-8. He was also a visiting professor at the University of Illinois at Chicago, December 15-16.
- **Amin Kassam, MD**, was an invited guest speaker at the Asian Oceanian International Congress on Skull Base Surgery in Dubai, United Arab Emirates, November 1-2; an invited guest speaker at the International Symposium on Microneurosurgical Anatomy in Antalya, Turkey, November 7-8 and an invited guest speaker at the German Society of Skull Base Surgery in Freiburg, Germany, November 10. He was also a visiting professor at Stanford University's Department of Neurological Surgery, December 15.

New Faculty

- **Naman A. Salibi, MD, MSc**, has joined the faculty as a clinical assistant professor working with Joseph Maroon, MD, and his colleagues at Tri-State Neurosurgical Associates. His primary interest is in spinal surgery including arthroplasty and minimally invasive procedures.
- **Theodore J. Spinks, MD**, has accepted a position as clinical assistant professor at Pediatric Neurosurgery at Children's Hospital of Pittsburgh. Dr. Spinks' clinical focus is on developing minimally invasive surgical techniques for children, especially in the areas of CSF diversion, intracranial and skull

base tumors, and spinal surgery.

New Employees

- **Ashlee Carter**, administrative assistant for Drs. Tyler-Kabara and Adelson; **Krystal Haley**, Coder 1; **Sue Kim**, CRNP for the endovascular program.

Personal Congratulations

- **Matthew Wetzel, MD**, and wife (Fotini Abatzis) had a baby daughter (Penelope Evdokia) born on Sunday November 19;
- **Pedro Aguilar, MD**, and wife (Trina) had a baby boy (Ricardo Pablo) born on November 22.

Upcoming Events

- February 28: **Visiting Professor**. Chandranath Sen, MD, Chairman, Department of Neurosurgery, St. Luke's Roosevelt Hospital Center, New York, NY.
- March 12-16: **Principles and Practice of Gamma Knife Radiosurgery**. For neurosurgeons, radiation oncologists and medical physicists interested in Gamma Knife radiosurgery certification. This course will also be offered May 14-18. Call (412) 647-7744 for registration information.
- April 25: **Visiting Professor**. Albert Rhoton, MD, Professor and Chairman Emeritus, Department of Neurosurgery, University of Florida, Gainesville, FL.



Department of Neurological Surgery
University of Pittsburgh Medical Center
UPMC Presbyterian/Suite B-400
200 Lothrop Street
Pittsburgh, PA 15213
(412) 647-3685
neuroinfo@upmc.edu

www.neurosurgery.pitt.edu



Patient Referrals
(412) 647-3685

Non-Profit
Organization
U.S. Postage
PAID
Permit #4166
Pittsburgh, PA



University of Pittsburgh Medical Center
Recognized as an honor roll member of *U.S. News & World Report's* 'America's Best Hospitals' 2006.

(see www.neurosurgery.pitt.edu for more details)

WINTER 2007 • VOLUME 8, NUMBER 1

Paleopathology adds to history of medicine

(continued from page 4)

the back supported by a trumpline around the forehead. Spinal tuberculosis (Pott's Disease) was relatively common. Surprisingly, examples of traumatic spinal injury were rare, as were compression fractures. Diseases of the spinal column in the ancient inhabitants of the Andean region of South America were similar to those that affect the present-day population of that area.

Another study with the collaboration from the Division of Neuropathology of our institution was the study performed on mummified human brains excavated from the same area. Specimens of dura mater, cerebral hemispheres, cerebellum, and spinal cord, were analyzed and described. Through a special tissue rehydration process, samples were taken for light and electron microscopic examination. Both normal as well as pathological processes were encountered. Individual neurons or axonal processes could not be clearly demonstrated.

Paleopathology has allowed us to better understand the neurosurgical disorders that were faced by man thousands of years ago. These congenital, degenerative, infectious, neoplastic, and traumatic disease processes are similar to those that modern day neurosurgeons encounter and treat. The study of ancient human remains through the field of paleopathology adds significantly to our understanding of the health of ancient populations and the history of medicine. Furthermore, the practice of medicine, the science and art of curing diseases, is a part of the field of anthropology, the science of man and mankind. •

Douglas Kondziolka installed as Peter J. Jannetta Professor



University of Pittsburgh chancellor Mark A. Nordenberg presents Douglas Kondziolka, MD—department vice chair of education and co-director of the Center for Image-Guided Neurosurgery—with a medal December 19, installing him as the Peter J. Jannetta Professor at the university.

Dr. Kondziolka is an internationally known expert in radiosurgery, stereotactic surgery and neuro-oncology. He is a leading researcher in the study of novel treatments for functional disorders including epilepsy and Parkinson's Disease and has performed groundbreaking studies in neuronal transplantation.

The endowed chair is one of five neurosurgery chairs held at the university and honors the career and accomplishments of Peter J. Jannetta, MD, chairman of the department from 1971-1997. Dr. Jannetta is widely hailed for his groundbreaking research into the pathology and innovative treatment of cranial nerve compression syndromes, particularly trigeminal neuralgia.