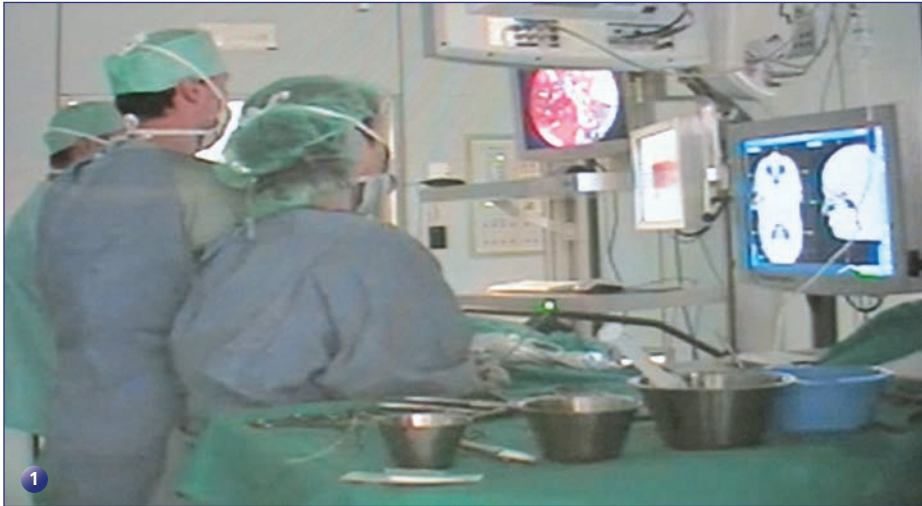



Cranial base team takes lead in telementoring surgical techniques across globe



1 Camera view of surgical team in Maribor, Slovenia performing an endoscopic pituitary surgery.

by Paul Gardner, MD; Carl Snyderman, MD

The UPMC Center for Cranial Base Surgery was the first such center established in North America and has been a pioneer and leader in developing new surgical techniques for the treatment of patients with tumors and other conditions affecting the base of skull, nasal and sinus areas, and some areas of the brain. In many cases, large tumors (both benign and malignant) can be completely removed without the need for a craniotomy and associated manipulation of the brain. This surgery is dependent on endoscopic technology. Visualization is provided by thin endoscopes while a team of surgeons (otolaryngologist and neurosurgeon) work together to remove the tumor. The surgery is technically demanding and requires extensive training over many years to achieve proficiency.

Outside of a limited number of training fellowships, the cranial base surgeons at UPMC teach several anatomical dissection courses at UPMC each year that are attended by surgeons from around the globe. Since 2005, more than 500 surgeons have been trained from over 30 countries. Many of these surgeons will spend extended lengths of time (weeks to months) observing cranial base surgeries as visiting scholars to enhance their learning experience. Despite such exposure, most of these surgeons will have difficulty achieving success with these procedures when they return to their own hospitals.

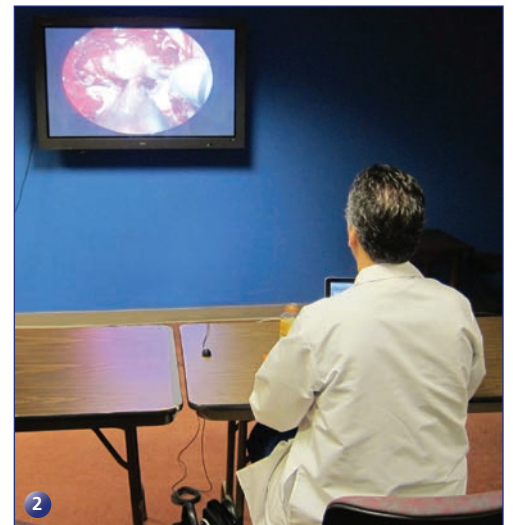In response to this need, the cranial base team at UPMC has created a surgical telementoring program to advance the training of surgeons globally at selected sites. Telementoring is the use of telemedicine technology to provide ongoing training while surgery is performed at a remote location. In November 2011, we performed the first telementored surgery at UPMC in cooperation with surgeons at the University of Maribor in Slovenia. While the surgeons in Maribor were performing an endoscopic pituitary surgery (*figure 1, above*), we observed from a conference room at UPMC (*figure 2, right*) and provided real-time feedback, giving advice about surgical anatomy, instrumentation, and surgical technique. The surgery was successful and the surgeons in Maribor felt that the telementoring contributed greatly to their confidence and ability to achieve their surgical goals. This has been followed by successful telementoring of a second skull base surgery in Slovenia.

With the demonstrated success of this initial experience, the UPMC Center for Cranial Base Surgery hopes to establish Centers of Excellence in Cranial Base Surgery globally through the use of telementoring. Selection criteria for telementoring sites are based on

geographic location, institutional resources, surgical capabilities, and clinical need. The process includes: (1) attendance of a skull base course in Pittsburgh by a surgical team with observation of surgeries; (2) on-site visit of the remote site by UPMC team to assess needs, resources, and capabilities. This may include on-site educational activities as well as mentoring of live surgeries; (3) remote telementoring of live cases with capture of data regarding impact on decisions and clinical outcome; and (4) follow-up on-site visit for further mentoring or educational activities.

Telemedicine is the use of telecommunication and information technology to provide clinical health care at a distance. UPMC is already a leader in developing applications for telemedicine, with successful programs in general surgery (consultations, postoperative care), dermatology (diagnosis), neurology (diagnosis and treatment of stroke patients), psychiatry, radiology, pathology, and others. Telemedicine technology has also been used to educate surgeons by televising surgeries worldwide while they are being performed by UPMC physicians in Pittsburgh.

The cranial base team at UPMC will be presenting their experience with surgical telementoring at the UPMC Telemedicine Symposium in Belgium this summer. This international conference will address all aspects of telemedicine and explore the future challenges of this exciting innovation. •



2 Carl Snyderman, MD, observes Slovenia procedure from Pittsburgh and provides real-time feedback.

CHAIRMAN'S MESSAGE

Brain tumor management requires multifaceted approach

A significant component of an academic neurosurgical department rests upon on its ability to effectively manage patients with brain tumors. The challenges presented by brain tumors are multifactorial. First, we must identify whether a tumor should be operated upon. Second, if the decision is made to operate, we must decide which is the best approach and what is the most effective modality. Many options exist, particularly in our department.

A fundamental defining characteristic of a leading department of neurosurgery is the ability to present different options to the patient and to offer the option that both minimizes the acute risks of a procedure and maximizes the likelihood for a good long-term outcome. As you can appreciate from this issue of our newsletter, neurosurgeons at the University of Pittsburgh Department of Neurological Surgery have the capability of providing a broad spectrum of techniques and expertise for patients with all types of brain tumors. Working in close collaboration with other departments including ear, nose and throat (ENT), radiation oncology, neuro-oncology, and anesthesiology, we can—in a collaborative and complementary fashion—develop individualized therapeutic plans tailored both to the specific patient as well as to the specific type of tumor.

Development of an individualized plan occurs through discussions at one of our several

multidisciplinary brain tumor conferences. Not being limited by the options or approaches available, we are able to accomplish—in a most effective fashion—our ultimate goal of delivering both minimally invasive approaches and, at the same time, maximally effective results.

Additionally, our faculty is involved in a multitude of cutting edge clinical trials. In close collaboration with our neuro-oncology and radiation oncology colleagues, we have the ability to provide our patients the choices and options that ultimately distinguish our center as an international leader in the management of all types of brain tumors.

Our highest priority is to deliver the highest level of clinical and technical expertise within a compassionate and caring environment. Our unwavering desire to provide the very best that medicine has to offer remains our guiding principle. Through our commitment to research and technical excellence, I look forward to seeing our department push the boundaries of what of what medicine can offer to develop more effective therapies for this often devastating group of diseases.



Robert M. Friedlander, MD, MA
*Chairman, Department of Neurological Surgery
UPMC Endowed Professor of Neurosurgery & Neurobiology
University of Pittsburgh School of Medicine
University of Pittsburgh Medical Center*

- Chairman**
Robert M. Friedlander, MD, MA
- Professors**
C. Edward Dixon, PhD
(Vice Chairman, Research)
Robert Ferrante, PhD
Peter C. Gerszten, MD, MPH
Michael B. Horowitz, MD
Larry W. Jenkins, PhD
Douglas S. Kondziolka, MD, MSc
(Vice Chairman, Education)
L. Dade Lunsford, MD
John J. Moosy, MD
Ian F. Pollack, MD
(Vice Chairman, Academic Affairs)
Mingui Sun, PhD

- Associate Professors**
Jeffrey Balzer, PhD
Arlan H. Mintz, MD, MSc
Ajay Niranjani, MD
Hideho Okada, MD, PhD
David O. Okonkwo, MD, PhD

- Assistant Professors**
David J. Bissonette, PA-C, MBA
(Executive Director)
Donald J. Crammond, PhD
Johnathan Engh, MD
Juan C. Fernandez-Miranda, MD
Paul A. Gardner, MD
Avniel Ghuman, PhD
Paola Grandi, PhD
Stephanie Greene, MD
Miguel Habeych, MD, PhD
Brian Jankowitz, MD
Adam S. Kanter, MD
Ava Puccio, PhD, RN
Shengjun Ren, PhD
R. Mark Richardson, MD, PhD
Richard M. Spiro, MD
Mandeep Tamber, MD
Elizabeth C. Tyler-Kabara, MD, PhD
Yu Zhang, PhD

- Clinical Professors**
Adnan A. Abila, MD
Matt El-Kadi, MD, PhD
(Vice Chair, Passavant Neurosurgery)
Joseph C. Maroon, MD
Daniel A. Wecht, MD, MSc

- Clinical Associate Professor**
Michael J. Rutigliano, MD, MBA

- Clinical Assistant Professors**
Pedro J. Aguilar, MD
Eric M. Altschuler, MD
Oren Berkowitz, MD
J. William Bookwalter, MD
Daniel M. Bursick, MD
David J. Engle, MD
David L. Kaufmann, MD
Parthasarathy D. Thirumala, MD
Matthew M. Wetzel, MD

- Research Assistant Professors**
Jonathan Bellotte, PhD
Diane L. Carlisle, PhD
Yue-Fang Chang, PhD
Wendy Fellows-Mayle, PhD
Esther Jane, PhD
Wenyan Jia, PhD
Hideyuki Kano, MD, PhD
Rekha Pal, MD
Daniel Premkumar, PhD
Hong Qu Yan, MD, PhD

- Clinical Instructors**
Jeff Bost, PA-C
Alessandro Paluzzi, MD

Some Key Department Phone Numbers

Brain Function & Behavior	(412) 647-7744	Gamma Knife	(412) 647-7744
Brain Trauma Research Ctr....	(412) 647-0956	MEG Brain Mapping Center..	(412) 648-6425
Brain Tumor	(412) 647-2827	Movement Disorders	(412) 647-7744
Carotid Disease.....	(412) 647-2827	Neurotrauma	(412) 647-1025
Cerebrovascular	(412) 647-2827	Neurosurgical Oncology	(412) 647-8312
CyberKnife	(412) 647-1700	Pediatric Neurosurgery	(412) 692-5090
Endonasal Surgery	(412) 647-6778	Spine	(412) 802-8199
Endovascular	(412) 647-7768	Synergy.....	(412) 647-9786

a patient's story: CONOR MCKIERNAN

A LOOK AT HOW NEUROSURGERY CARE AFFECTS ORDINARY LIVES

by Zach Butovich

Conor McKiernan is a normal 11-year-old boy who loves to play baseball and watch the Yankees. He lives in a suburb of Los Angeles, gets A's and B's in school, and is popular in his classes. There is nothing about him that suggests that only six months ago he underwent surgery to remove a large and potentially fatal tumor that had been growing inside his nasal cavity.

Two years ago, Conor began to complain of allergy symptoms which worsened dramatically in recent months. Despite the advice of local medical experts, including allergists, pediatricians, and dieticians, Conor's symptoms did not improve. Conor also lost hearing in his right ear.

Eventually an otolaryngologist discovered a strange "growth" in Conor's nasal cavity. The doctor ordered a CT scan.

Later that week, Conor received an MRI confirming the size and location of a massive tumor growing in his nasal cavity and intracranial region. Conor's parents sent copies of the images to over thirty hospitals around the country and called dozens of physicians, surgeons, and Ear, Nose and Throat specialists, desperately seeking help. Finally,

a diagnosis came back—Conor had juvenile nasopharyngeal angiofibroma, a specific type of tumor that exclusively affects young males and is often characterized by a very rich blood supply that makes surgical removal extremely difficult. Conor's tumor had already grown large enough to have eroded the bone separating his sinuses from his brain, and extended intracranially, actually pushing up against critical tissue.

Carl Snyderman, MD, co-director of the Center for Skull Base Surgery, was the first physician to return a telephone call from Conor's mother, Jill Schwartz. Dr. Snyderman, who has a joint appointment in otolaryngology and neurology, confidently told Jill that he had seen a number of cases like Conor's before and had extensive operating experience with this type of tumor.

Many of the other physicians expressed concern about the size of the tumor, the risk of bleeding from the major arteries to the brain, and the difficulty of reaching a tumor so close to the brain. Divergent opinions were presented to the family, and included recommendations ranging from open brain surgery to minimal surgery with radiation therapy. Others declared Conor inoperable, and the endoscopic approach as "too cavalier."

Dr. Snyderman assured Conor and his parents that with the assistance of his partner, Center for Skull Base Surgery co-director Paul Gardner, MD, he was positive that the whole tumor could be removed endoscopically through the nose and mouth. Despite their trepidations, the McKiernan's were eventually convinced by the confidence and experience of the UPMC team at the Center for Skull Base Surgery team.

Conor's family soon learned that The Center for Skull Base Surgery at UPMC is the world leader in skull base surgery—a minimally invasive technique that allows surgeons to access the back of the nasal cavity, throat, neck and head—and that Drs. Snyderman and Gardner comprise the leading surgical team in the endoscopic endonasal approach.



Conor McKiernan with Drs. Paul Gardner (left) and Carl Snyderman (right).

On September 23, 2011, Conor underwent his first surgery with Drs. Snyderman and Gardner. After his second surgery a week later, the doctors came out of the operating room, looked at Jill and Conor's father, Kieran, and said, "We got it all." "At that moment," recalled Jill, "we felt an indescribable joy."

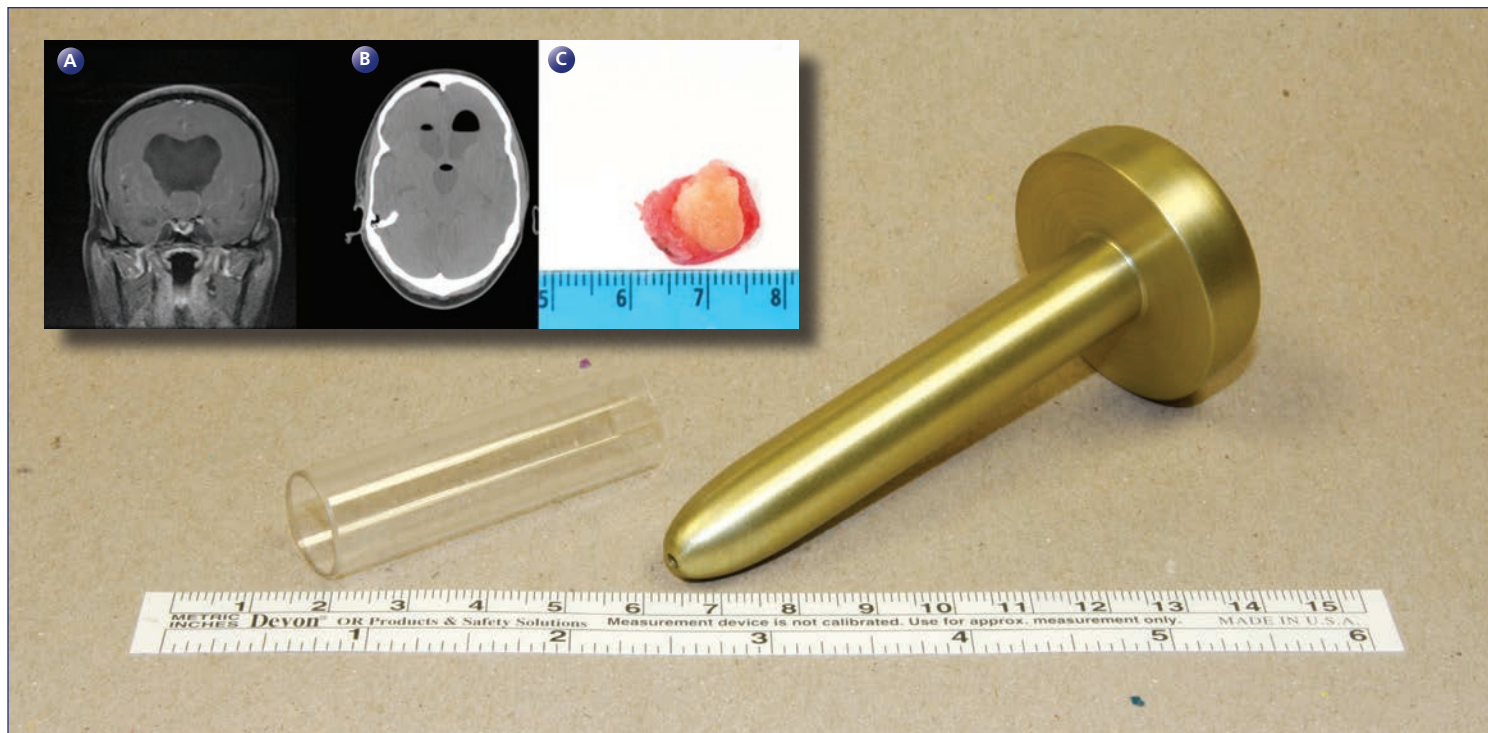
Following the successful surgery, and since their return to California, Jill and her husband have been actively helping out the Center for Skull Base Surgery by soliciting philanthropic support for the center's international training program, which is in urgent need of new equipment for surgical training with an emphasis on endoscopic techniques. The center attracts surgical students from around the world, helping them to learn and refine techniques that will save lives in communities on every continent. Jill is dedicated to helping us find support so others can feel the joy and elation she felt when Drs. Snyderman and Gardner told her, "we got it all." "Not a minute goes by that I don't think about it," Jill said.

Conor has been doing fantastic since his recovery in October. On Halloween he went trick or treating as a "mad surgeon." "This is something very special that you have in Pittsburgh," Jill said recently over the phone, "If there ever was such a thing as a "Hollywood ending," you provided it for our family."

For information about supporting the Center for Skull Base Surgery, contact Jim Olsen at (412) 647-7781. •



Endoscopic port surgery for colloid cyst resection: The best of both worlds?



(main image): Oblique view of the bullet shaped dilator and the transparent endoscopic port used for EPS, with a ruler for scale purposes; **(inset images):** **(A):** Pre-operative coronal T1 MRI scans demonstrate a massive colloid cyst of the third ventricular roof with foraminal obstruction and hydrocephalus. **(B):** The cyst was removed in its entirety using an endoscopic port, as demonstrated on intraoperative CT scan with expected pneumocephalus. **(C):** The pathologic specimen demonstrated marked calcification, which precludes through-channel endoscopic resection.

by Johnathan Eng, MD

Although colloid cysts represent a small fraction of all adult brain tumors (~1%), their surgical management has been a subject of controversy for decades. Colloid cysts may present with headache, confusion, dizzy spells, memory dysfunction, or even syncope. In rare cases, patients may develop sudden death from untreated obstructive hydrocephalus associated with the colloid cyst. However, these lesions are eminently treatable and usually curable with surgery alone; therefore, optimization of surgical treatment of these patients is a worthwhile goal.

Classical surgical management of colloid cysts consists of microsurgical resection of the cyst, either via an interhemispheric transcallosal approach or a transcortical transfrontal approach. While typically curative, these approaches can be associated with cognitive disability, venous injury, and post-operative seizures, to name a few of the most worrisome complications. Working channel endoscopic fenestration and resection of colloid cysts emerged as a less invasive alternative to conventional microsurgical resection more recently. While working channel endoscopy appears

to offer lower complication rates and shorter hospital stays than conventional microsurgical resection, recurrence rates are much higher than with conventional resection. In addition, this approach is not feasible for calcified cysts or for patients with small ventricles.

Endoscopic port surgery (EPS) for resection of colloid cysts emerged at UPMC about a decade ago (NeuroendoportSM). Based on surgical concepts pioneered by Patrick Kelly, MD, the Neuroendoport was initially designed by L. Dade Lunsford, MD, who modified surgical access ports for endoscopic thoracic surgery to make them compatible with a stereotactic head frame.

Using this frame, an 11.5 mm port can be placed into the ventricle over a bullet shaped dilator and a brain needle with remarkable accuracy (*main image above*). Following placement of the port, the ventricular space is converted into an air medium in which a rod lens endoscope provides parallel light and magnification. The cyst is then resected using bimanual microsurgical technique.

Dr. Lunsford partnered with Amin Kassam, MD, who performed the endoscopic cyst resection following stereotactic port placement. Since 2008, I have directed the

Neuroendoport program at UPMC. Over the past four years, we have removed over 200 intracranial lesions (colloid cysts, intraventricular tumors, and intraparenchymal tumors) using this innovative technology.

Endoscopic port resection of colloid cysts offers advantages of both microsurgical cyst resection and through channel endoscopy. Like microsurgery, EPS facilitates complete removal of the cyst wall and subsequent cure of the cyst. Calcified cysts and cysts in patients with small ventricles are highly resectable with this technique (*inset image above*). Like standard endoscopy, EPS creates a single, small transcortical channel into the ventricle, decreasing the risk of postoperative cognitive deficit, seizures, and venous injury, and facilitating shorter hospital stays (average stay 2.7 days post resection in our series).

While EPS still has risks, our data suggests that it is an effective and safe approach for colloid cyst resection in appropriate hands. Future research is focusing on the development of even smaller endoscopic ports and better tools for cyst removal, as well as cognitive testing paradigms designed to further improve outcomes for these challenging patients. •

Awake craniotomies offer ability to safely resect maximum amount of tumor

by Arlan Mintz, MD

Awake craniotomies refer to cranial operations on conscious patients able to participate in speech and motor tasks. Historical use of awake craniotomy includes excision of epileptogenic foci and resection of tumors in eloquent cortex. Eloquent cortex refers to areas of the cerebrum that subserve critical functions such as speech, motor, sensation, vision and hearing. Resection of brain tumors that are within or invading into these critical areas represents a challenge for neurosurgical oncologists. The use of awake intraoperative mapping has been shown to be the most reliable method for localizing eloquent cortex and its associated subcortical white matter during tumor resection.

There is an evidence-based trend in neurosurgical oncology in favor of a maximal resection of primary brain tumors. Unfortunately, the infiltrative and aggressive malignant gliomas comprise the majority of primary brain tumors and have a median survival of 12-18 months.

The goals of surgical resection include determining cellular histology and molecular pathology that aide in targeted therapy as well as achieving a maximal resection. Maximal tumor resection has been demonstrated to provide improvement in neurological function by decreasing the mass effect and reliance on corticosteroids. However, there is an increasing volume of evidence that extent of resection also affects length of survival. The current challenge in neurosurgical oncology is the neurosurgeons ability to maximally resect tumors without causing worsening or new neurological deficits.

There are many tools in the neurosurgical oncologist armamentarium to map and navigate around eloquent brain regions. This is initiated with pre-operatively advanced imaging including functional MRI's or magnetoencephalograms (MEG) to identify the specific regions in our patients that subserve language and motor functions. UPMC has developed and uses high definition fiber tractography to localize the critical fiber tracts emanating from these eloquent areas. We then use this information and correlate critical functional areas to the location and extent of the tumor. However, the most accurate method for determining the location of eloquent cortical regions is by directing mapping these regions during awake surgery.

The techniques for cortical mapping have been developed and refined by Penfield and Ojemann. These techniques, combined with advancements in neuroanesthesia and neuronavigation, provides the modern neurosurgeon with the ability to safely resect brain tumors on awake patient using cortical mapping and intra-operative speech and motor assessments to achieve maximal tumor resection with reduced operative morbidity.

Close communication between the neurosurgeon and the anesthesia team is critical for the success of these procedures. The process is initiated with intravenous sedation combined with scalp nerve blocks. The sedation continues during the image guided minimally invasive skin, bone and dural opening. The patient is then awakened and intraoperative testing with cortical stimulation begins. Eloquent areas are identified and the cortical incision and tumor resection is done with the patient awake and communicating with the operative team and neurophysiologist.

During resection, motor or speech tasks continue to ensure normal brain function is preserved. The main advantage to operating on an awake patient is the intraoperative identification of eloquent regions that allows the surgeon to execute a greater tumor resection with more confidence and reduced neurological injury. Additionally, there is decreased ICU admission and length of stay as well as avoiding foley catheters.

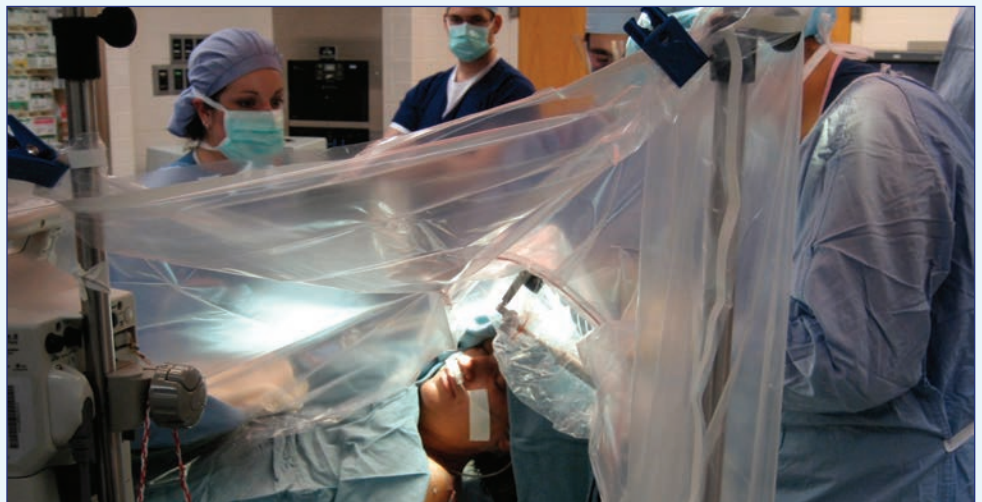There is evidence from the literature and our own experience that awake craniotomy is safe and well tolerated. Published literature supports both better neurological outcomes and greater tumor resection. In

addition, areas that have been shown to have negative mapping provide additional information to the surgeons to allow for a greater resection of surrounding regions containing infiltrative tumor.

In our most recent series from 2009-2012, we have completed over 60 awake craniotomies for intra-axial supratentorial tumors and one cavernous malformation. The case distribution included 29 patients with malignant gliomas (48%), 14 with low grade gliomas (23%) and 17 with metastatic disease (28%). Only, one patient required conversion to general anesthesia during resection, due to uncontrollable coughing. Over 60% of patients were discharged on post-operative day one.

At UPMC Shadyside we have developed, and are validating, an advanced anesthesia operative protocol for awake craniotomies that includes pre-operative criteria to determine which patients are best suited for awake craniotomies.

Potential benefits of operating on an awake and functioning brain reflect not only improved neurological outcomes, but an ability to more safely resect a greater amount of tumor which impacts overall survival. Awake craniotomies require cooperation from an experienced surgeon and anesthesiologist along with intraoperative guidance from the neurophysiology team to maximize success in achieving a relaxed and comfortable patient. This team approach is the key to our success in ensuring patient cooperation and allows us to push the boundaries for maximal amount of tumor resected while continuously assessing the patient to ensure no new deficits are occurring. •



During an awake craniotomy, the patient is lightly sedated, providing feedback to neurosurgeons to help assess the extent of a tumor resection.

Examining the role of radiosurgery in treatment of glioblastomas

by L. Dade Lunsford, MD; Douglas Kondziolka, MD; Ajay Niranjana, MD

Glioblastoma continues to be a devastating illness with more than 10,000 new cases in the United States each year. Despite advances in image-guided surgery, chemotherapeutic options, and recently the usage of bevacizumab, the median survival of glioblastoma has not changed significantly. More recently, however, we have seen improvement in the percentage of patients who are living at two and five years.

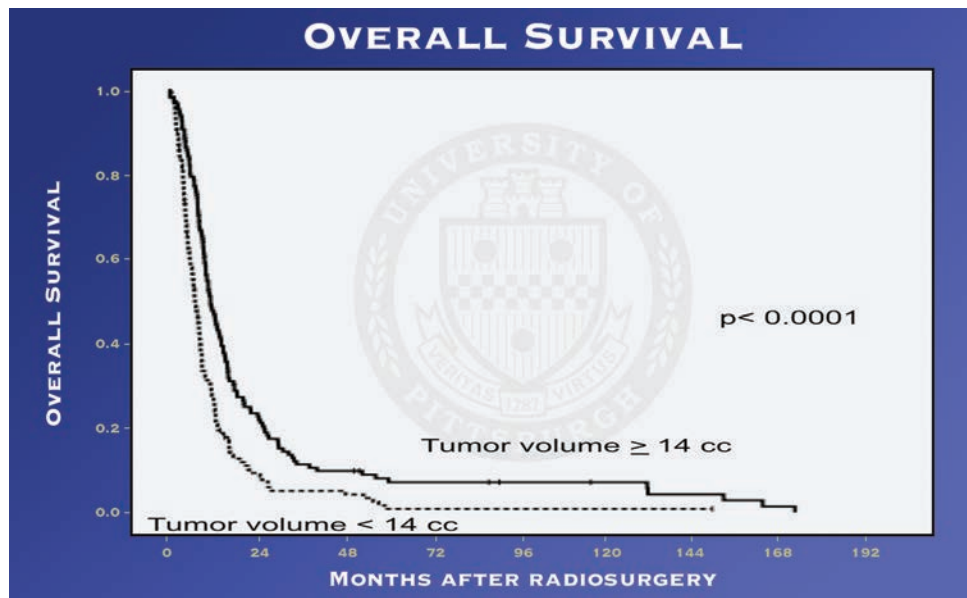
The standard management of glioblastoma consists of surgical resection when feasible, especially for tumors located in lobar brain regions, followed by conventional fractionated external-beam radiation therapy. Most patients enter treatment using the STUPP regimen which adds temozolomide chemotherapy during the radiation therapy treatment component and then increases the dose of temozolomide after completion.

Over the years, radiation therapy has proved to be the treatment standard which must be applied to all patients to increase the response rate and improve median survival. Our approach has been to try to maximize the benefit of radiation modalities by using radiosurgery as an adjuvant in the treatment of glioblastoma during multimodality treatment of glioblastoma patients.

We have recently completed a retrospective outcome analysis of 297 patients who underwent Gamma Knife radiosurgery as part of the treatment regimen between 1988 and 2007. Two-thirds of our patients also had concomitant temozolomide, and all patients received postoperative conformal, fractionated external-beam radiation therapy (median dose of 60 Gy in 2 Gy fractions).

Gamma Knife radiosurgery was performed using precise head-frame guidance coupled with intraoperative MRI scan to identify the target volume. Gross tumor volume was defined as the paramagnetic contrast enhancing tumor edge. Patients received boost radiosurgery (median dose) to the tumor margin of 15 Gy.

Outcome measures included overall survival from the initial diagnosis, overall survival after radiosurgery, and progression free survival. In this series of patients, the median survival time from diagnosis was 17.7 months (95%, CI 16.4-19.0 months). Factors associated with improved overall survival were younger-



age, smaller tumor volume, and the prior use of chemotherapy. The median survival time after radiosurgery was 8.9 months. Patients whose tumor volumes were 14 cc or larger were compared to patients whose tumors were smaller (less than 14 cc) (*see table above*). The one-year, two-year, and five-year survivals after radiosurgery in patients with tumor volumes less than 14 cc were 47.8%, 11.6%, and 8.1%. Patients with larger tumor volumes had one-year survivals of 27.7%, 9.4%, and 0.9%. No patient suffered acute morbidity or early toxicity from adding radiosurgery. Adverse radiation effects, if detected, were noted at an average of 1.7 months in 20% of patients. The procedure was well tolerated by all patients otherwise.

Glioblastoma remains a challenging clinical disorder. The addition of a multimodality treatment option that includes radiosurgery (and followed by the additional use of bevacizumab), will hopefully continue to improve median survivals as well as increase the percentage of patients who survive one to five years or more.

Early introduction of radiosurgery in conjunction with bevacizumab may be a potent combination treatment for eligible patients. Bevacizumab may improve the radiobiological response of radiosurgery and at the same time reduce the detection of adverse radiation effects.

In conjunction with industry and multiple participating centers of the North American Gamma Knife Consortium, we anticipate a clinical trial using radiosurgery with bevacizumab. We plan to expand the target volume to include the contrast-enhancing

volume plus a 1 cm “border zone.” It is this “border zone” adjacent to the contrast-enhancing tumor mass that represents the area of delayed progression and clinical recurrence in most patients. •

Childhood glioma study

(continued from back page)

These studies take advantage of unique institutional resources provided by the University of Pittsburgh Cancer Institute Immunological Monitoring and Cellular Products Laboratory, which evaluate various parameters of immune response in children treated on this study.

Patients from age 18-months to 21 are currently being recruited for five distinct strata: 1) newly diagnosed brainstem gliomas treated with irradiation; 2) newly diagnosed non-brainstem malignant gliomas treated with irradiation; 3) newly diagnosed malignant gliomas in patients who have received chemo-irradiation therapy; 4) recurrent malignant gliomas; 5) progressive recurrent low-grade gliomas.

To date, 28 children have been treated, and although the results are preliminary, three children have had objective evidence of tumor regression on MRI and all but four of the others have had disease stabilization through at least two vaccine cycles, in many cases substantially longer. Eleven of 13 patients who have undergone immunological evaluation have shown at least some response to the vaccine antigens. •

Friedlander, Pollack Elected to Prestigious AAP

Robert M. Friedlander, MD, UPMC Endowed Chair of Neurological Surgery and Chairman of the Department of Neurological Surgery, and **Ian Pollack, MD**, Walter E. Dandy Professor of Neurological Surgery and Chief of Pediatric Neurosurgery at Children's Hospital of Pittsburgh, were recently elected to the Association of American Physicians (AAP), a prestigious nonprofit, professional organization founded in 1885 for the advancement of scientific and practical medicine.

According to the AAP website, "to be a member of the most prestigious Association of American Physicians is a great honor. Members have included Nobel laureates, and members of the National Academy of Science and the Institute of Medicine. Each year, selected members of the international scientific community also nominated by the Council as honorary members of the Association. Today, the Association continues to serve as a repository of the best medical minds and as a forum to promote friendship, to create and disseminate knowledge, and to provide role models for upcoming generations of physicians and medical scientists."

Drs. Friedlander and Pollack are two of only three neurosurgeons serving as members of the organization.

Friedlander to Receive Winn Prize

Dr. Friedlander has been selected to receive the 2012 H. Richard Winn, MD Prize from the Society of Neurological Surgeons.

According to the SNS website, "The purpose of this international award is to encourage research in the neurosciences and to recognize outstanding, continuous commitment to research in the neurosciences by a neurological surgeon. This prize both recognizes the accomplishments of Dr. Winn, and seeks to reward a neurological surgeon who has made, and continues to make, substantial contributions to clinical or basic neuroscience."

The award will be presented to Dr. Friedlander at the society's annual meeting scheduled for Atlanta, GA, May 19-22.

Vertebral Body Compression Fracture CME Course

UPMC Physician Services is now offering a free online CME course on vertebral body compression fractures featuring **Peter Gerszten, MD**. The 48-minute presentation covers the epidemiology, costs, and different management strategies for vertebral body compression fractures, including literature that supports interventional management strategies. To view the presentation, please visit UPMCPHYSICIANRESOURCES.COM/NEUROSURGERY. You'll also find two other courses on the site. One on pituitary tumors, the other dealing with cranial base surgery.

New Book Volume

L. Dade Lunsford, MD, is co-editor of a newly released book volume, *Current and Future Management of Brain Metastasis*, published by Karger. The book discusses up-to-date guidelines for brain metastasis control and practical points on how to deal with difficult situations in daily clinical practice. It is the latest volume in the publisher's *Progress in Neurological Surgery* series. Dong Gyu Kim, MD, of the Hallym University Medical Center, in Seoul, South Korea, is co-editor of the book. Dr. Lunsford is also series editor of the *Progress* series.

In the Media

- **Dr. Pollack**, received wide-spread media attention in April for his study that demonstrated a peptide vaccine can produce positive results in fighting gliomas in children. (*See related article on back page*). The study's findings were reported in *U.S. News & World Report*, MSN.com, Health.com, and WTAJ-TV (Johnstown) among others.

- **David O. Okonkwo, MD, PhD**, was featured in a March 2 issue of the *Pittsburgh Tribune Review* detailing how High Definition Fiber Tracking (HDFT) can help doctors tailor treatments for people with traumatic brain injuries.

Dr. Okonkwo was also featured in a related Associated Press wire article March 21 discussing how HDFT research could help doctors pinpoint underlying causes in traumatic brain injuries and guide rehabilitation in TBI patients.

- A TBI patient of **Dr. Okonkwo**, Alisha Webb, and her grandmother, Regina Venturella, appeared on the KDKA Radio *Morning News*, February 6, talking about Alisha's dramatic recovery from brain injuries suffered in an automobile accident. Regina wrote a book on Alisha's recovery titled, *It Only Took A Moment*. Portions of sale proceeds from the book will go to support brain trauma research at the University of Pittsburgh.

- **Joseph Maroon, MD**, was a guest on the KDKA-FM (The Fan 93.7) *Morning Sports Radio Show*, March 14, talking about concussion research and return-to-play considerations for athletes returning from major head and neck problems such as Peyton Manning and Sidney Crosby.

Dr. Maroon was also interviewed on the KDKA-TV 2 *Evening News*, March 12, commenting on the traumatic brain injury and post traumatic stress disorder of an Iraqi war veteran.

Prominent Lectures and Appearances

- **Douglas Kondziolka, MD**, was a visiting professor at New York University, February 3; State University of New York at Buffalo, February 9; and Stanford University, April 20.

- **Dr. Friedlander** was keynote speaker at the 25th Annual Korean Society for Cerebrovascular Surgery held in Jeju, South Korea, February 17.

- **Jeffrey Balzer, PhD**, was a distinguished visiting professor at the University of Florida Department of Neurosurgery, April 12-13.

- **Adam Kanter, MD**, was guest of honor and speaker at the Brazilian Spine Congress Annual Meeting held in Sao Paolo, Brazil, this past March.

Congratulations

- **Dr. Friedlander**, was recently selected as chair-elect of the AANS/CNS Joint Section of Cerebrovascular Surgeons.

- An article by **Mark R. Richardson, MD, PhD**, entitled 'Interventional Magnetic Resonance Imaging-Guided Stereotactic Surgery' was selected as an editor's choice in the March issue of the national science publication, *Operative Neurosurgery*.

- **Arlan Mintz, MD**, was promoted to associate professor of neurological surgery at the University of Pittsburgh.

Welcome

- **Cristina Ruiz**, clinical assistant for Richard Spiro, MD.



Department of Neurological Surgery
University of Pittsburgh Medical Center
UPMC Presbyterian/Suite B-400
200 Lothrop Street
Pittsburgh, PA 15213
(412) 647-3685
neuroinfo@upmc.edu

Non-Profit
Organization
U.S. Postage
PAID
Permit #4166
Pittsburgh, PA

www.neurosurgery.pitt.edu



UPMC

Recognized as an honor roll member of *U.S. News & World Report's* 'America's Best Hospitals' 2010-11

SPRING 2012 • VOLUME 13, NUMBER 2

Promising immunotherapy trial continues for deadly childhood gliomas

by Ian Pollack, MD

Malignant astrocytomas are among the most common and deadly brain tumors of childhood. Most children with brainstem gliomas and malignant gliomas arising elsewhere in the brain die within several years of diagnosis, despite treatment. Low-grade gliomas can also prove treacherous; while most children with superficial lesions of the cerebellum and cerebral hemispheres are cured with surgical tumor removal, lesions in deep sites, such as the hypothalamus and brainstem, rarely can be removed completely and carry high risks for recurrence and long-term side effects.

During the past decade, researchers at the University of Pittsburgh, led by Hideho Okada, MD, PhD, have gained significant preclinical and clinical experience with immunotherapy for adult gliomas, and building upon these data, we questioned whether these insights could be applied

to the treatment of children with gliomas. Recently published studies from our laboratories demonstrated substantial similarities between pediatric and adult gliomas in their expression of glioma-associated antigens (GAAs), which provided the foundation for our clinical protocol to examine the efficacy of peptide-based vaccination against these antigens in children.

This clinical study and biological correlative analyses represented the first application of a multi-peptide epitope vaccine-based strategy for the treatment of children with gliomas, and was supported by an R21 grant from the National Cancer Institute, a Program Project Grant from the National Institute for Neurological Diseases and Stroke, and a grant from the Pediatric Low Grade Glioma Initiative. The overarching goal of this study was to provide fundamental data for assessing safety, and clinical and immunological efficacy, of immunotherapeutic strategies in the pediatric brain tumor context.

Along with pediatric oncologist Regina Jakacki, MD, Dr. Okada and I have developed a GAA-based vaccine cocktail, combined with an immunoadjuvant (poly-ICLC) to further boost immune response. The trial, which is open to accrual, includes children with newly diagnosed malignant brainstem gliomas, newly diagnosed subtotally resected non-brainstem malignant gliomas, recurrent malignant gliomas and treatment-refractory low-grade gliomas.

Participants are treated with subcutaneous injections of GAA vaccines every three weeks for eight courses, and poly-ICLC is administered as a separate intramuscular injection on the same day as each vaccination. Participants are evaluated for treatment-related side effects and treatment response by clinical and laboratory evaluations and MR imaging. Participants who demonstrate disease stabilization or regression without unacceptable toxicity can receive additional vaccinations.

(continued on page 6)